

Use of Denosumab in an Aneurysmal Bone Cyst of the Spine.

Case Report and Literature Review

Felipe Lanari Zubiaur,^{*} Alfredo O. Godoy Adaro,^{**} Pedro L. Bazán[#]

^{*}Grupo Médico Vertebral, Autonomous City of Buenos Aires, Argentina

^{**}Clínica Modelo S. A., Paraná, Entre Ríos, Argentina

[#]Hospital Interzonal General de Agudos "General San Martín", La Plata, Buenos Aires, Argentina

ABSTRACT

Vertebral tumors of the spine have a very low frequency. The incidence of aneurysmal bone cyst (ABC) ranges between 1% and 4% of all tumors. Its predominant location is the lumbar spine, to a greater extent, in the posterior arch. According to published studies, this condition behaves aggressively, due to the root compression generated by its expansion. While there is literature on the surgical treatment of the tumor and its en bloc resection and embolization, there is no experience on the treatment with monoclonal antibodies. There are very few published articles that corroborate a treatment for recurrences or for inoperable or intralesional aneurysmal bone cysts, which leave the possibility open to other techniques. We present the case of a 38-year-old woman with lumbar pain radiating to the thigh. In studies, a tumor was detected, and the needle biopsy and imaging confirmed that it was an aneurysmal bone cyst. We planned the treatment with preoperative embolization and intracompartmental excision by subsequent surgery with the release of the dural sac. At six months, tumor recurrence was observed. Treatment with denosumab was indicated for two years, periodic controls were carried out and the remission of symptoms and improvement in the images were verified.

Key words: Aneurysmal bone cyst; treatment; relapse; coadjuvant; denosumab.

Level of Evidence: IV

Uso de denosumab para el quiste óseo aneurismático de columna. Reporte de un caso y revisión bibliográfica

RESUMEN

Los tumores vertebrales de columna tienen una frecuencia muy baja. La incidencia de quiste óseo aneurismático (QOA) oscila entre el 1% y el 4% de todos los tumores. Su ubicación predominante es la columna lumbar, en mayor medida, en el arco posterior. Según estudios publicados, esta enfermedad se comporta de forma agresiva, por la compresión radicular que genera debido a su expansión. Si bien hay bibliografía sobre el tratamiento quirúrgico del tumor y su resección en bloque y embolización, no se dispone de experiencias sobre el tratamiento con anticuerpos monoclonales. Existen muy pocos artículos publicados que corroboren un tratamiento para las recidivas o para los quistes óseos aneurismáticos inoperables o intralesionales, los cuales dejan la posibilidad abierta a otras técnicas. Presentamos el caso de una mujer de 38 años con lumbocuralgia. En los estudios, se detecta una tumoración, y la biopsia por punción y las imágenes confirman que se trata de un quiste óseo aneurismático. Se planifica el tratamiento con embolización preoperatoria y exéresis intracompartmental mediante cirugía posterior con liberación del saco dural. A los seis meses, se observa la recidiva del tumor. Se indica tratamiento con denosumab por dos años, se realizan controles periódicos y se constata la remisión de los síntomas y la mejoría de las imágenes.

Palabra clave: Quiste óseo aneurismático; tratamiento; recidiva; coadyuvante; denosumab.

Nivel de Evidencia: IV

Received on May 17th, 2020. Accepted after evaluation on November 4th, 2020 • Dr. PEDRO L. BAZÁN • pedroluisbazan@gmail.com  <https://orcid.org/0000-0003-0060-6558>

How to cite this article: Lanari Zubiaur F, Godoy Adaro AO, Bazán PL. Use of Denosumab in an Aneurysmal Bone Cyst of the Spine. Case Report and Literature Review. *Rev Asoc Argent Ortop Traumatol* 2021;86(6):821-828. <https://doi.org/10.15417/issn.1852-7434.2021.86.6.1121>

INTRODUCTION

Vertebral tumors in the spine have a very low frequency, 1-4% correspond to aneurysmal bone cyst (ABC).¹⁻¹⁰ ABC is an expansive benign tumor. Although it was considered a pseudotumor for many years, it has currently been shown that it is a benign tumor associated with a specific altered pattern in the USP6 gene located on chromosome 17p13.^{1,2}

In 70% of patients, ABC is detected as a single presentation and, in 30%, it is associated with other tumors. It is frequent in the lumbar spine with a predominance in the posterior arch. Its most distinctive characteristics include slow growth, blood islets separated by connective septa,^{1,2,6-8} and aggressive behavior due to the root compression resulting from its expansion.^{6,7,9}

From the histological point of view, ABCs are characterized by having multinucleated giant cells and stromal cells, originating from mesenchymal osteoblast cells. It is an aggressive benign tumor,^{1-3,6,10} which, according to Enneking classification, varies from stages 1 to 3.^{1,2}

In general, patients present pain and stiffness; if it appears in the spine, the symptoms can be aggressive due to spinal or root compression and include pathological fractures due to tumor extension, instability, or neurological deficit.^{6,7,9}

Treatments for ABC in the lumbar spine and pelvis have been a surgical challenge, since their approach and complications remain an obstacle to definitive treatment. Although the first line of approach has been selective arterial embolization and en bloc resection,^{1-3,6-8,10} adjuvant techniques have been established to treat patients who are not candidates for embolization or have unresectable or recurrent tumors after these treatments.^{2,3,6,7,9} One of the possible adjuvant therapeutic options is the use of denosumab, a fully human monoclonal antibody that inhibits the RANKL (receptor activator of nuclear factor kappa-B ligand) and whose effect is to drastically decrease bone resorption in tumors of these characteristics, which are shared with giant cell tumors.^{2,3,7-9,11}

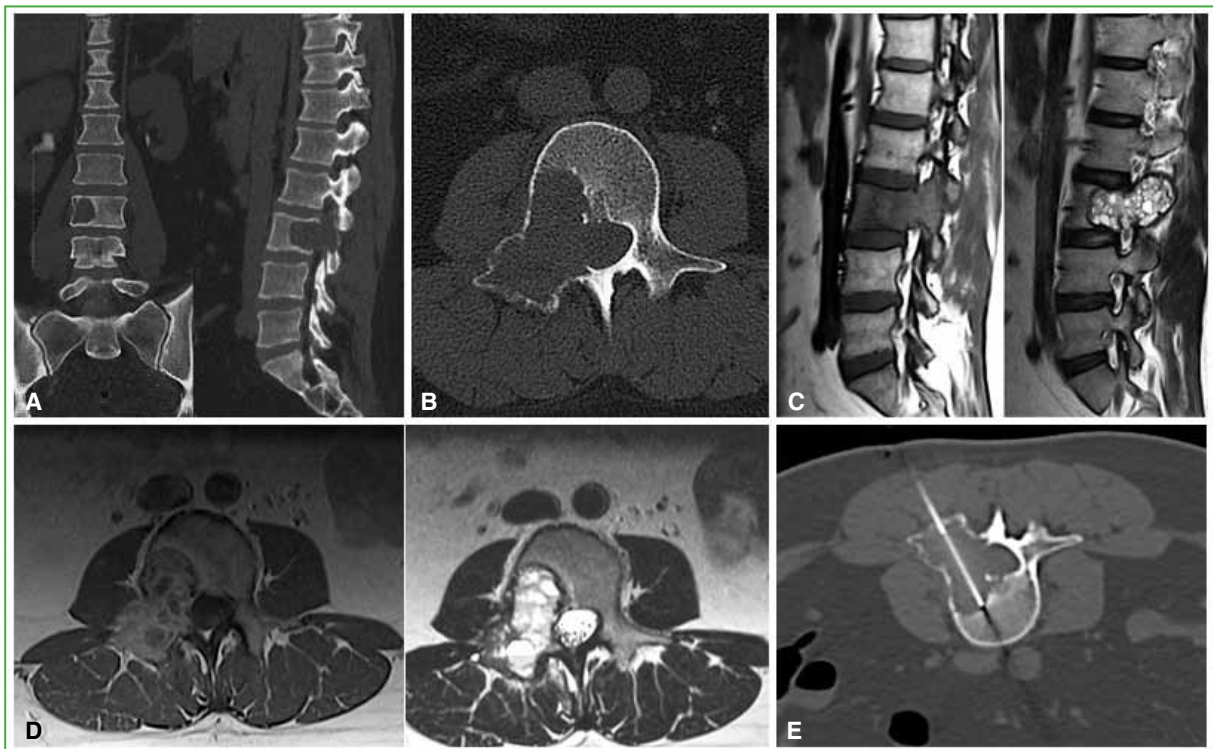


Figure 1. Initial studies. Lumbosacral spine multiplane tomography. **A.** Coronal and sagittal planes. **B.** Axial plane showing a fragile wall lesion on the medial pedicle wall. Lumbosacral spine magnetic resonance. **C.** Sagittal plane in T1 and T2 sequences. The cystic lesion that compromises the body and inflates the pedicle and facet joints is observed. **D.** Axial plane in T1 and T2 sequences. Canal compromise is displayed. **E.** Tomographic image of the fine needle biopsy puncture.

We present this case to examine the use of denosumab in patients with ABC recurrence and assess the effects of the dose over time and the possibility of performing surgery after treatment.

CLINICAL CASE

A 38-year-old woman came to the consultation with lumbar pain extending to the thigh (predominantly on the right) that increased over time. She had no motor deficit, the hips were free, the Lasegue test was negative, and the Wasserman test was positive with prevalence on the right side. We detected bilateral patellar hyporeflexia with superficial and deep hyperesthesia of right L3 and L4, cavovarus foot, and bilateral positive pulses. The patient said she suffered from gallstones. She brought a total body bone scan and single-photon emission computed tomography (SPECT) with 20/30 mCi of ^{99m}Tc that reported a single lesion in L3; a previous tomography of the thorax, abdomen, and pelvis that did not reveal findings of metastasis or any other possible tumor focus, before the puncture to determine the type and lineage of the pathology in question; and a BI-RADS 2 mammogram showing no tumor disease.

Other imaging studies, helical tomography and magnetic resonance imaging, were requested, and the location of the lesion within the vertebra was confirmed. Tomography-guided needle biopsy (Figure 1) confirmed the diagnosis of ABC.

Two months after the consultation and the studies, the cyst had a torpid evolution and the symptoms increased; therefore, new studies were requested in which the progression and even a pathological fracture in the body of L3 were observed (Figure 2).

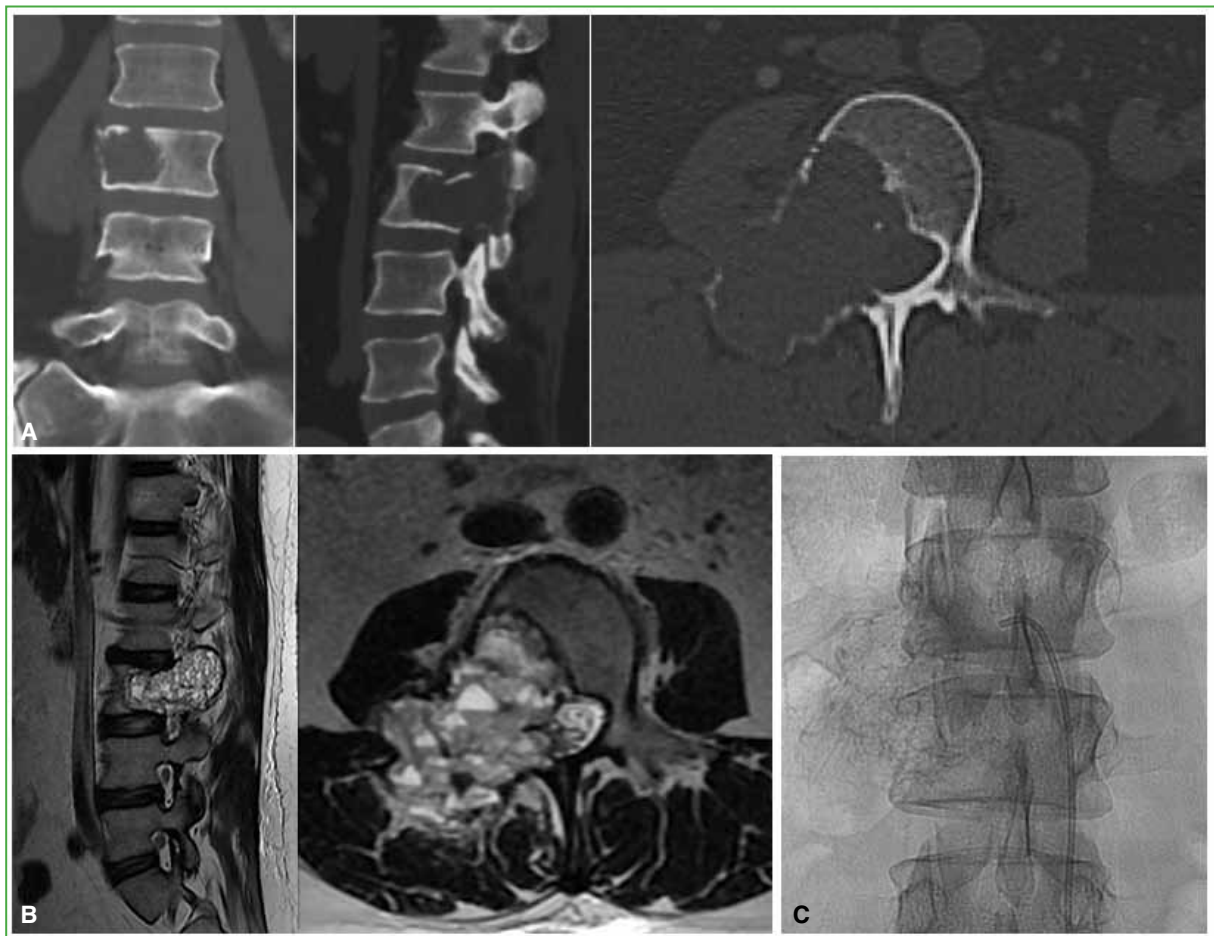

Figure 2. Complementary studies two months after diagnosis that show the progression of the disease. **A.** Lumbosacral spine multiplane tomography, coronal, sagittal, and axial planes. **B.** Lumbosacral spine magnetic resonance, sagittal and axial planes. **C.** Preoperative fluoroscopic embolization.

We decided to evaluate the treatment possibilities for this patient and the points considered were: that it was a rapidly progressive benign lesion, type G0III (aggressive), extracapsular, and extracompartmental M0, according to Enneking's classification; that the patient had no symptoms of potential instability at the time of the examination; and that she presented progressive neurological disorders. After analyzing the literature, we opted for selective pre-embolization. 24 h before the intervention, we performed a posterior approach, excised the intracompartmental lesion with phenol as an adjuvant substance, and reamed the lesion. Then, we proceeded to release the dural sac and the roots of L2 and also of L3 with arthrodesis of the L2, L3, and L4 vertebrae (Figure 3). The postoperative evolution was good.

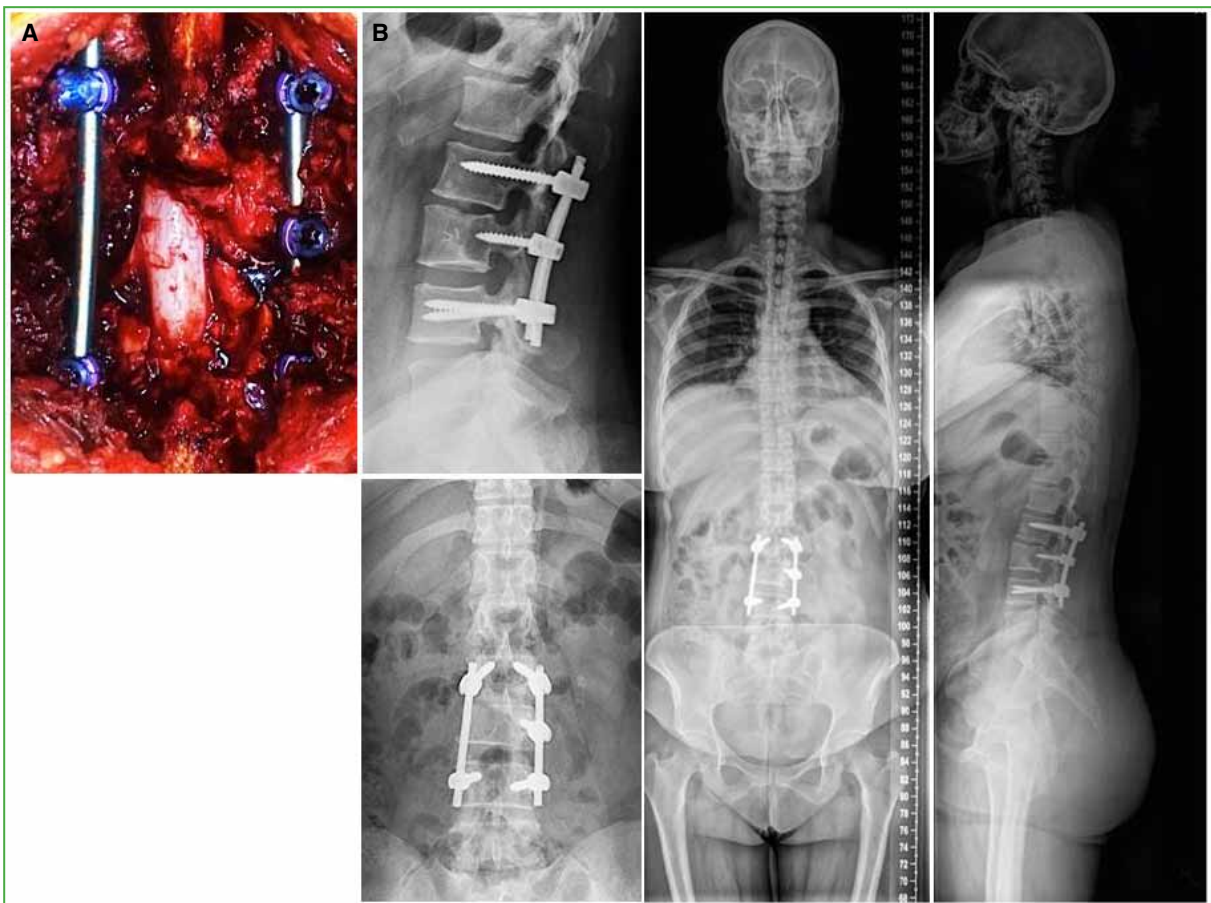


Figure 3. A. Intraoperative image. B. Postoperative radiographs and spinogram.

Six months after the procedure, the patient presented no symptoms. The computed tomography and the control magnetic resonance imaging (Figure 4) showed an image compatible with a local recurrence of the ABC. After consulting the literature cited in this article, the new treatment was discussed with the following options: new L3 vertebrectomy, intratumoral injections of corticosteroids and calcitonin, tumor embolization, and administration of denosumab. We chose treatment with denosumab 120 mg, initial dose, every three months for two years. At the medium-term, a tomographic control was performed and the remission and calcification of the lesion were verified (Figure 5).

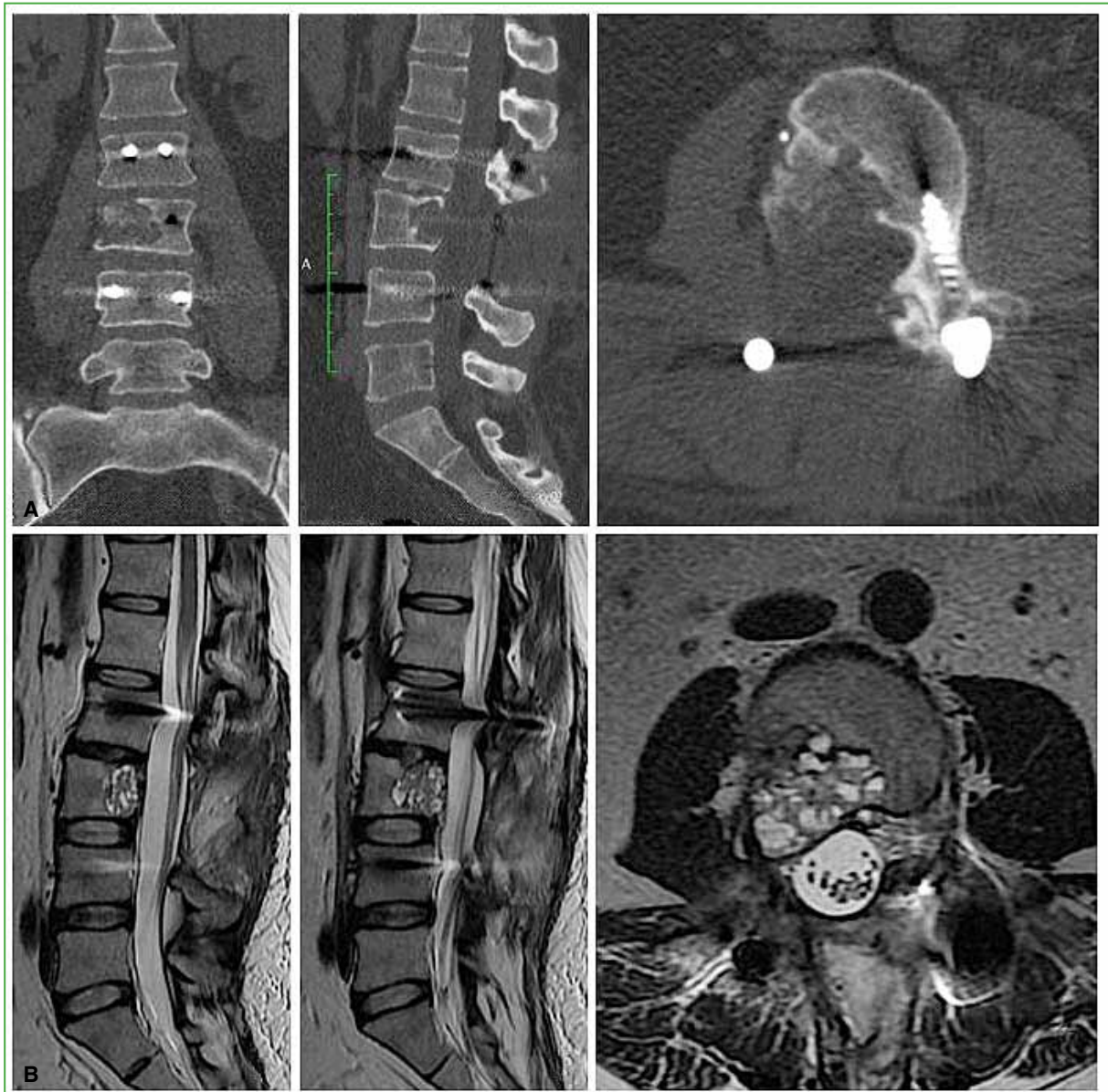


Figure 4. Computed tomography (A) and magnetic resonance imaging (B) six months after surgery. The recurrence of the tumor is observed.

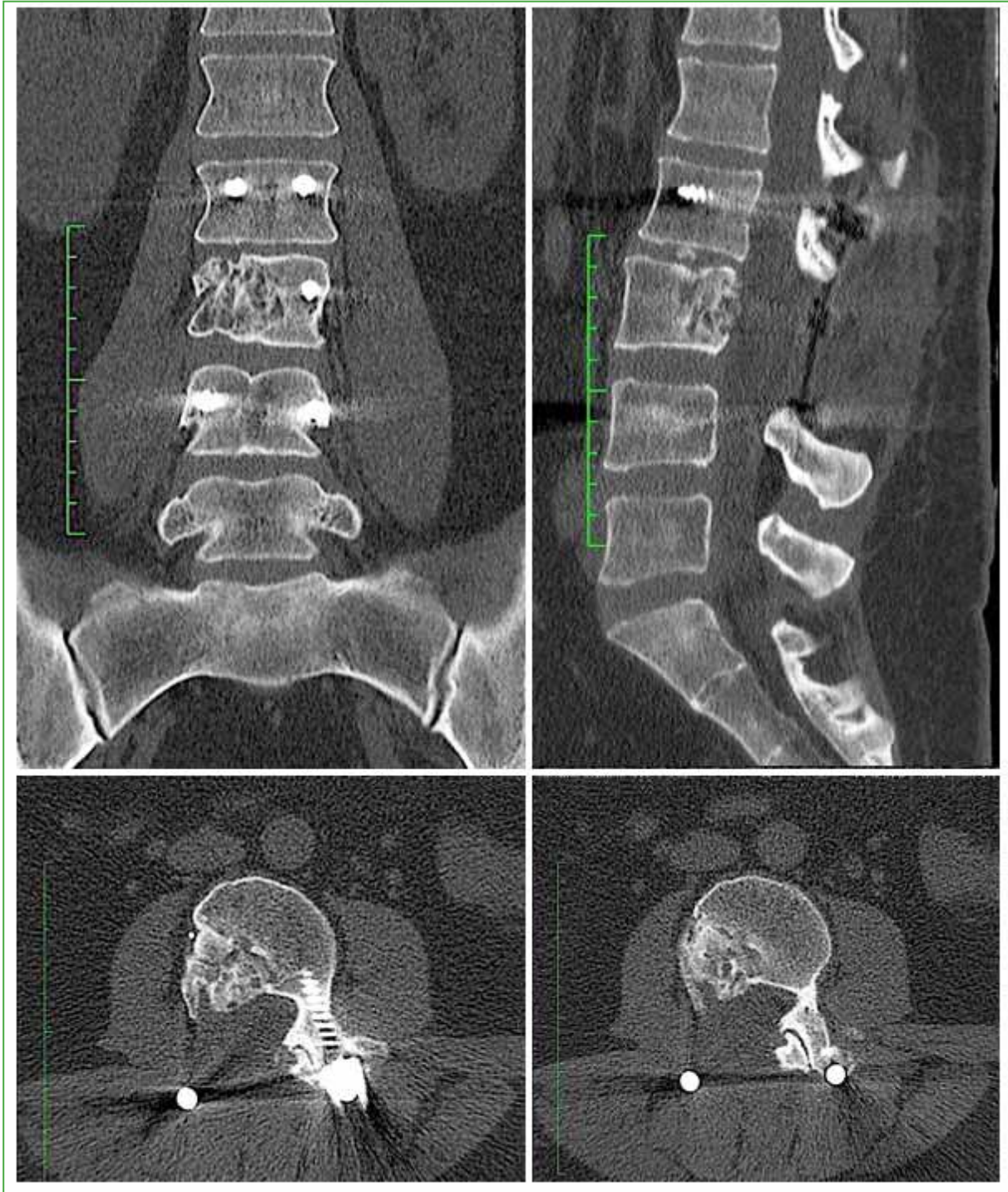


Figure 5. Control computed tomography after one year of treatment with denosumab.

DISCUSSION

The use of denosumab for the initial treatment of tumors is currently under discussion, but it could be a therapeutic possibility for tumors located in areas that are difficult to access with surgical techniques^{1,7,9} or even for local recurrences of ABC, since it has been shown that it allows bone formation and tumor regression,⁷⁻⁹ which translates into a reduction or remission of the patient's clinical picture and a radiological improvement of the tumor. The maximum efficacy of the treatment is achieved at six months.⁹ Although the results with denosumab are currently auspicious, as in our case, it must be taken into account that the efficacy of this drug has been demonstrated in preliminary studies, and data on long-term safety, recurrences, and optimal long-term duration are inconclusive. Therefore, trials with more cases and longitudinal and clinical studies are needed to support the duration and consistency of denosumab treatment in ABC.^{3,6,8-10}

CONCLUSIONS

The administration of denosumab 120 mg as the initial dose, and then a dose every three months, up to two years, was beneficial for our patient with a local recurrence after embolization and tumor excision. Total remission and calcification were achieved. The use of this drug remains controversial before surgery, as there is insufficient evidence from patients treated in this way.

Conflict of interest: The authors have no conflicts of interest to declare.

F. Lanari Zubiaur ORCID ID: <https://orcid.org/0000-0003-4030-0959>

A. O. Godoy Adaro ORCID ID: <https://orcid.org/0000-0001-8018-9197>

REFERENCES

1. Terzi S, Gasbarrini A, Fuiano M, Barbanti Brodano G, Ghermandi R, Bandiera S, et al. Efficacy and safety of selective arterial embolization in the treatment of aneurysmal bone cyst of the mobile spine. *Spine* 2017;42(15):1130-8. <https://doi.org/10.1097/BRS.0000000000002017>
2. Ghermandi R, Terzi S, Gasbarrini A, Boriani S. Denosumab: non-surgical treatment option for selective arterial embolization resistant aneurysmal bone cyst of the spine and sacrum. Case report. *Eur Rev Med Pharmacol Sci* 2016;20(17):3692-5. PMID: 27649673
3. Lange T, Stehling C, Fröhlich B, Klingenhöfer M, Kunkel P, Schneppenheim R, et al. Denosumab: a potential new and innovative treatment option for aneurysmal bone cysts. *Eur Spine J* 2013;22(6):1417-22. <https://doi.org/10.1007/s00586-013-2715-7>
4. Namazi H. Letter regarding "Denosumab: a potential new and innovative treatment option for aneurysmal bone cysts". *Eur Spine J* 2013;22(10):2342. <https://doi.org/10.1007/s00586-013-2951>
5. Lange T, Schulte TL. Answer to the Letter to the Editor of H. Namazi concerning "Denosumab: a potential new and innovative treatment option for aneurysmal bone cysts" by Lange T, Stehling C, Fröhlich B, Klingenhöfer M, Kunkel P, Schneppenheim R, Escherich G, Gosheger G, Hards J, Jürgens H, Schulte TL (2013), *Eur Spine J*; 22(6):1417-1422. *Eur Spine J* 2013;22(10):2343. <https://doi.org/10.1007/s00586-013-2956-5>
6. Patel RS, Dhamne AC, Kumar, GA, Kumar N. Denosumab: a potential treatment option for aneurysmal bone cyst of the atlas. *Eur Spine J* 2018;27 (Suppl 3):S494-S500. <https://doi.org/10.1007/s00586-018-5528-x>
7. Kurucu N, Akyuz C, Ergen FB, Yalcin B, Aydin B, Varan A, et al. Denosumab treatment in aneurysmal bone cyst: evaluation of nine cases. *Pediatr Blood Cancer* 2018;65(4):e26926. <https://doi.org/10.1002/pbc.26926>
8. Skubitz KM, Peltola JC, Santos RC, Cheng EY. Response of aneurysmal bone cyst to denosumab. *Spine* 2015;40(22):E1201-E1204. <https://doi.org/10.1097/BRS.0000000000001027>
9. Dubory A, Missenard G, Domont J, Court C. Interest of denosumab for the treatment of giant-cells tumors and aneurysmal bone cysts of the spine. About nine cases. *Spine* 2016;41(11): E654-E660. <https://doi.org/10.1097/BRS.0000000000001350>

10. Charest-Morin R, Boriani S, Fisher CH, Patel S, Kawahara N, Mendel E, et al. Benign tumors of the spine. Has new chemotherapy and interventional radiology changed the treatment paradigm? *Spine* 2016;41(20):S178-S185. <https://doi.org/10.1097/BRS.0000000000001818>
11. Bazán PL, Di Falco R, Borri AE, Medina M, Ciccioi NM, Danielle S. The use of denosumab in giant cell tumors in sacrum. *Coluna/Columna* 2020;19(2):147-9. <https://doi.org/10.1590/S1808-18512020190228839>