

# Modular Fluted Tapered Stems in Revision Total Hip Arthroplasty. Multicenter Study. Medium-term Results and Complication Rate

Santiago L. Iglesias,\* Fernando Vanoli,\* Leonel Pérez Alamino,\*\* Ignacio Pioli,\* José Gómez,\* Fernando A. Lopreite,\*\* Pablo Maletti,# Hernán del Sel,\*\* Bartolomé L. Allende\*

\*Department of Child Orthopedics and Traumatology, Sanatorio Allende, (Córdoba, Argentina)

\*\*Orthopedics and Traumatology Service, Hospital Británico de Buenos Aires (Buenos Aires, Argentina)

#Traumatología del Comahue (Neuquén, Argentina)

## ABSTRACT

**Background:** The number of arthroplasties performed every year is increasing; therefore, a greater number of revisions is expected in the coming decades. Modular fluted tapered stems have become the gold standard for their results in different series of patients. The objective of this article is to evaluate the results, complications and the survival rate of these stems in hip revisions with a medium-term follow-up. **Materials and Methods:** Retrospective, multicenter analysis. One hundred eighty-two patients who had undergone hip revision surgery between 2007 and 2017 were included. One hundred eighty-five modular fluted tapered stems were placed. Femoral bone stock defects were classified according to Paprosky and Burnett; and periprosthetic femur fractures according to Vancouver classification. Patients were evaluated clinically with Harris Hip Score (HHS) and radiographically 3 months after surgery and every year to assess stem stability, subsidence and loosening, as well as osteotomy healing. **Results:** Average follow-up was 55.18 months. Postoperative HHS had an average of 80.28 (SD = 12.8, 95% CI = [78.5, 82.97]). There were no postoperative complications in 75.4% of the patients. The most frequent complications were instability in 7.6% and implant subsidence in 11.5%. At the end of the follow-up, 95.05% of the patients had a stable implant. **Conclusion:** Modular fluted tapered stems provide a reliable, reproducible solution for the management of femoral component revisions at medium-term.

**Key words:** Hip joint; arthroplasty; hip replacement; femur; prosthesis failure.

**Level of Evidence:** IV

## Vástagos estriados cónicos modulares en revisión de artroplastia total de cadera. Estudio multicéntrico. Resultados y complicaciones a mediano plazo

## RESUMEN

**Introducción:** Debido al crecimiento exponencial del número de artroplastias de cadera, se espera una mayor cantidad de revisiones en las próximas décadas. Los vástagos cónicos estriados modulares se han vuelto populares en la última década por sus resultados favorables. El objetivo de este estudio es evaluar los resultados, las complicaciones y la tasa de supervivencia de estos vástagos en las revisiones de cadera, con un seguimiento a mediano plazo. **Materiales y Métodos:** Estudio multicéntrico, retrospectivo. Se incluyeron 182 pacientes a quienes se les realizó una cirugía de revisión de cadera entre 2007 y 2017. Se colocaron 185 vástagos cónicos estriados de fijación distal. El déficit de stock óseo femoral se clasificó según Paprosky y Burnett; y las fracturas periprotésicas, según la clasificación de Vancouver. Se evaluó a los pacientes clínicamente con el Harris Hip Score (HHS) y con radiografías a los 3 meses y anualmente para evaluar la estabilidad del vástago, la subsidencia y el aflojamiento, así como la consolidación de la osteotomía. **Resultados:** Seguimiento medio 55.18 meses. El HHS posoperatorio tuvo una media de 80,28 (DE = 12,8, IC95% 78,5-82,97). No hubo complicaciones posoperatorias en el 75,4% de los pacientes. Las complicaciones más frecuentes fueron inestabilidad (7,6%) y subsidencia del implante (11,5%). Al final del seguimiento, el 95,05% de los pacientes tenía un implante estable. **Conclusiones:** Los vástagos cónicos estriados modulares de fijación distal proporcionan una solución confiable, reproducible y duradera para el manejo de revisiones de componentes femorales a medio plazo.

**Palabras clave:** Articulación de cadera; artroplastia; reemplazo articular; fémur; falla de prótesis.

**Nivel de Evidencia:** IV

Received on May 15<sup>th</sup>, 2020. Accepted after evaluation on September 14<sup>th</sup>, 2020 • SANTIAGO L. IGLESIAS, MD • santiglesias07@hotmail.com  <https://orcid.org/0000-0001-6698-2914>

**How to cite this article:** Iglesias SL, Vanoli F, Pérez Alamino L, Pioli I, Gómez J, Lopreite FA, Maletti P, del Sel H, Allende BL. Modular Fluted Tapered Stems in Revision Total Hip Arthroplasty. Multicenter Study. Medium-term Results and Complication Rate. *Rev Asoc Argent Ortop Traumatol* 2021;86(2):197-206. <https://doi.org/10.15417/issn.1852-7434.2021.86.2.1118>

## INTRODUCTION

Total hip replacement is a highly effective procedure that relieves pain, improves function and quality of life, and grants the patient reasonable satisfaction and independence. Despite the success of total hip replacement, a small percentage of patients require multiple surgeries, often related to the failure of the femoral component. Due to the exponential growth in the number of hip replacements, a greater number of revisions are expected in the coming decades.<sup>1</sup> Although the revision of the femoral component with the use of cemented implants has already been described,<sup>2</sup> at present, cementless prostheses have gained great popularity, achieving better clinical and radiological results.<sup>3-5</sup>

There are numerous surgical techniques when considering the revision of the femoral component, such as cemented stems with or without bone graft,<sup>6-10</sup> allograft-prostheses<sup>11,12</sup> and uncemented stems of different designs, for example, extensively porous-coated stems<sup>13-15</sup> modular and nonmodular fluted tapered stems.<sup>16-21</sup>

Modular fluted tapered stems have become popular in the last decade for their favorable results in small series<sup>17,20,22</sup> and the reproducibility of their technique.<sup>23</sup> They have been reported to have lower rates of stress-shielding and implant subsidence.

The aim of this study was to evaluate the results, complications and revision rate with the use of fluted tapered stems for distal fixation in the revisions of the femoral component performed in three Level I centers, in our country, after a medium-term follow-up.

## MATERIALS AND METHODS

Retrospective multicenter study. The inclusion criteria were: patients who had undergone hip revision surgery between 2007 and 2017 and who received distal fixation fluted tapered stems, regardless of the cause of the revision, sex and comorbidities. 182 patients who received 185 distal fixation fluted tapered stems were included. All patients underwent surgery in three Level I centers by specialist surgeons in the area.

Preoperative planning included radiographic evaluation of the previous implant and the femoral bone stock deficit, which was classified according to Paprosky and Burnett.<sup>24</sup> According to the surgical technique, a minimum diaphyseal fixation of 5 cm was considered necessary to ensure correct distal fixation; when this was not possible, it was decided to use another surgical technique.<sup>25</sup> Two patients had a type I Paprosky defect; 40 cases, type II; 62, type IIIA; 34, type IIIB and 11, type IV.

For periprosthetic femoral fractures, we used the Vancouver classification.<sup>26</sup> One patient had a type B1 fracture; 16, type B2 and 19, type B3.

Implant subsidence was measured from fixed landmarks on the prosthesis to fixed landmarks on the femur.<sup>27</sup> Implant loosening was defined as progressive implant subsidence or a continuous radiolucent line around the femoral component.<sup>28</sup>

All patients were operated in lateral decubitus, with a posterolateral approach. ZMR® (Zimmer®), Restoration® (Stryker®), Reclaim® (DePuy Synthes, Inc.), Prevision® (Aesculap®), MPTM (Link®) and Arcos® (Biomet) modular stems were used, according to the surgeon's preference, regardless of the cause of the femoral revision.

In the immediate postoperative period, full weight-bearing was routinely allowed, within tolerance, with a walker regardless of the type of bone defect. Patients with intraoperative fractures were prescribed 50% weight bearing on the affected leg. On the other hand, all followed a strict protocol with hip mobility precautions (flexion, abduction, and internal rotation) for six weeks. The patients received antibiotic prophylaxis in preoperative and immediate postoperative doses, and antithrombotic prophylaxis for 28 days.

The clinical follow-up was conducted at 3 and 6 weeks, 3 months and 1 year after surgery. Then, patients were controlled annually. For the clinical evaluation, the Harris Hip Score (HHS)<sup>29</sup> was used and radiographs were taken at 3 months and annually to evaluate the stability of the stem, subsidence and loosening, as well as the consolidation of the osteotomy.

## STATISTICAL ANALYSIS

An exploratory data analysis (summary measures, frequency distribution tables and graphs - box plots, bar diagram and histogram) of the sample of patients was conducted, characterizing by sex, age, and the investigated characteristics.

To study the association between the type of implant, its result after follow-up, the presence or absence of previous interventions (and their number), the causes of femoral revision, the presence of complications, as well as sex and age, Poisson linear logarithmic models (more than two dimensions or crossovers of variables) and contingency tables were estimated, with the chi-square test (two-dimensional association), establishing a significance level equal to 0.05. Likewise, Pearson's correlation coefficients were estimated when the variables were quantitative (HHS, follow-up time, age) and the average difference of these was tested according to sex, previous implantation, etc., using the Student's test and analysis of variance. When the distribution was normal, the confidence intervals were also obtained using a 95% confidence level.

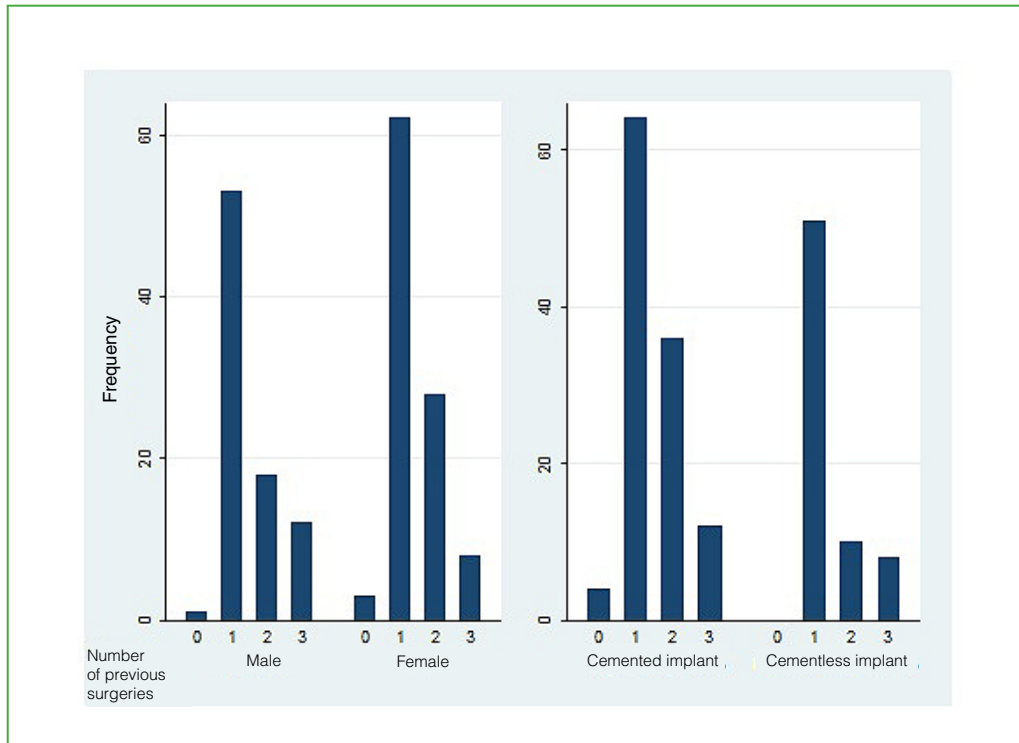
## FINDINGS

The average follow-up was 55.18 months, a value that was conditioned by 10% of the patients, who only had a single follow-up radiographic evaluation within the first postoperative year, but who, nevertheless, were clinically controlled by telephone. The average age was 64.97 years. A hundred and one patients (55.49%) were female and 81 (44.51%) were male (Table). 37% of the 182 patients included had cementless stems as previous implants, without statistically significant differences in relation to sex ( $p = 0.610$ ). 62% and 25% had already undergone surgery on one or two occasions, respectively, 10% had three or more previous surgeries. There were no statistically significant differences regarding sex ( $p = 0.37$ ) (Figure 1).

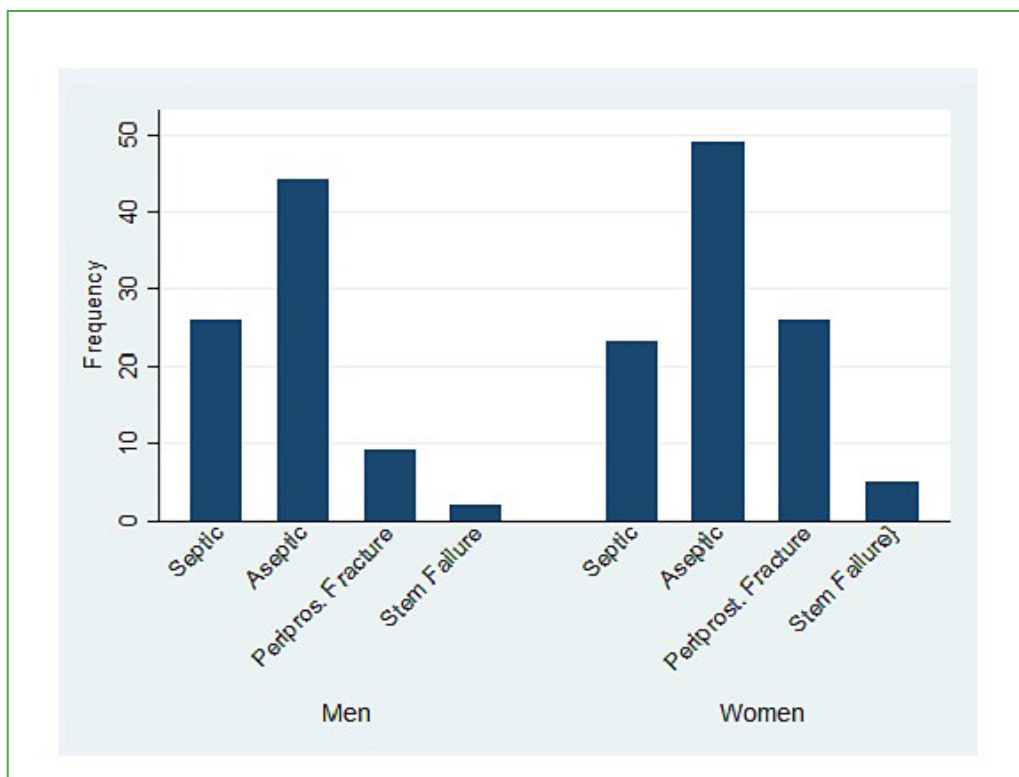
Regarding the causes of femoral revision, age was not a predisposing factor for this event ( $p = 0.745$ ). Revision surgeries of the femoral component were secondary to aseptic loosening (85 cases; 45.95%), septic loosening (two-stage revision) (54 cases; 29.19%), periprosthetic fracture (36 cases; 19.46%), stem fractures (7 cases; 3.78%) and instability (3 cases; 1.62%). When sex was correlated with the cause of the revision, statistically significant differences were observed ( $p = 0.047$ ) (Figure 2).

**Table.** Demographic data

|   |              |
|---|--------------|
| <b>Sex</b>  |              |
| Female  | 101 (55.49%) |
| Male  | 81 (44.51%)  |
| Average age   | 64.97 years  |
| Femoral bone defect<br>Paprosky Classification              |              |
| Type I  | 2 (1.34%)    |
| Type II   | 40 (26.85%)  |
| Type IIIA   | 62 (41.61%)  |
| Type IIIB   | 34 (22.82%)  |
| Type IV   | 11 (7.38%)   |
| Periprosthetic femoral fracture<br>Vancouver Classification |              |
| Type B1   | 1 (2.78%)    |
| Type B2   | 16 (44.44%)  |
| Type B3   | 19 (52.78%)  |
| Average follow-up   | 55.18 months |



**Figure 1.** Frequency distribution of patients according to the number of previous surgeries and sex (left) and implant outcome (right).

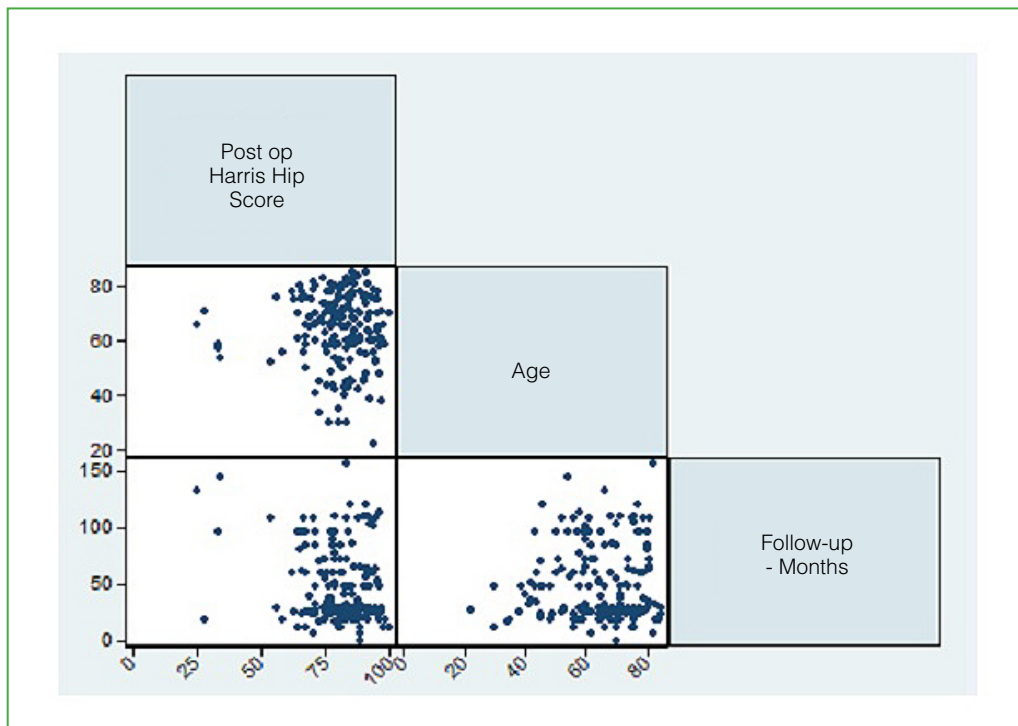


**Figure 2.** Frequency distribution of patients according to the causes of revision and sex.

The postoperative HHS had a average of 80.28 (standard deviation = 12.8; 95% confidence interval [95% CI] 78.5-82.97), 25% of the patients were below 75.5 and another 25% had values above 88.3. No statistically significant differences were found in relation to age ( $p = 0.334$ ), follow-up time (Figure 3), previous implant ( $p = 0.843$ ) or the number of previous surgeries ( $p = 0.33$ ). HHS was not correlated with sex either ( $p = 0.394$ ) (95% CI 78.2-84.14 and 77.4-81.8 for men and women, respectively).

When analyzing intraoperative complications, 2.19% (4 patients) had an intraoperative fracture at the time of placing the stem, without affecting the definitive stability of the implant.

75.4% of the patients did not suffer postoperative complications. Fourteen (7.6%) had an episode of instability. This influenced the postoperative HHS, which showed significant differences ( $p = 0.047$ ) with those who did not have dislocations. Another complication observed was subsidence of the stem (11.5%), with an average of 4.1 mm at the end of follow-up.



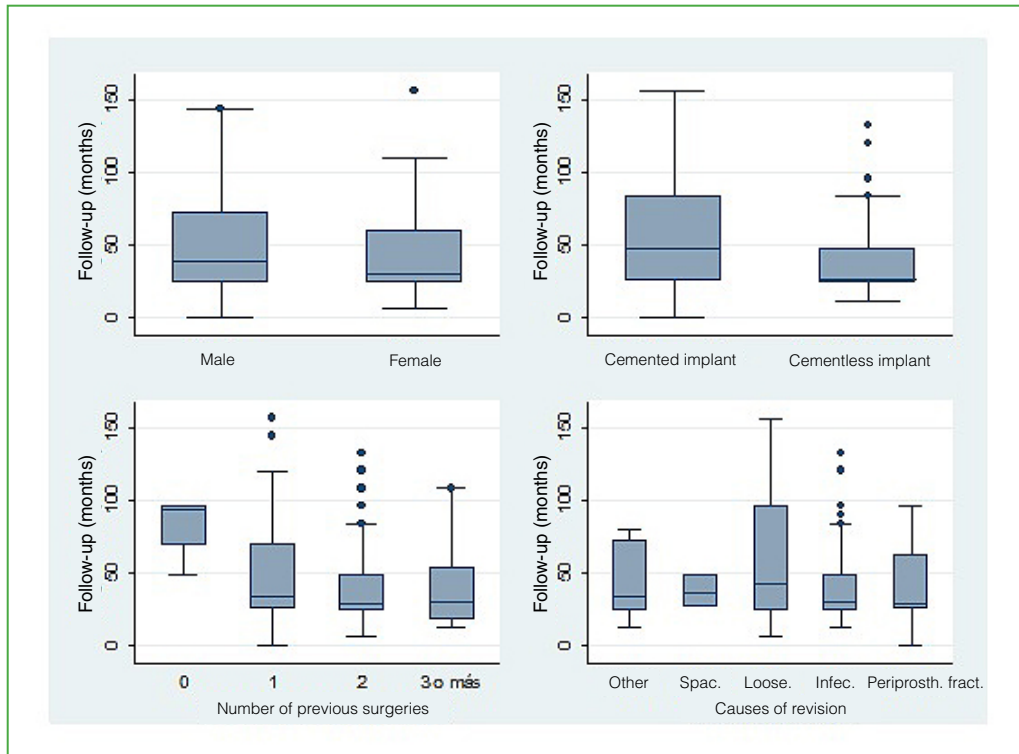
**Figure 3.** Scatter plot between the postoperative Harris Hip Score, age and follow-up time (months) of the patients.

These complications were not associated with sex ( $p = 0.882$ ), age ( $p = 0.372$ ) or previous implant ( $p = 0.225$ ) (Figure 4).

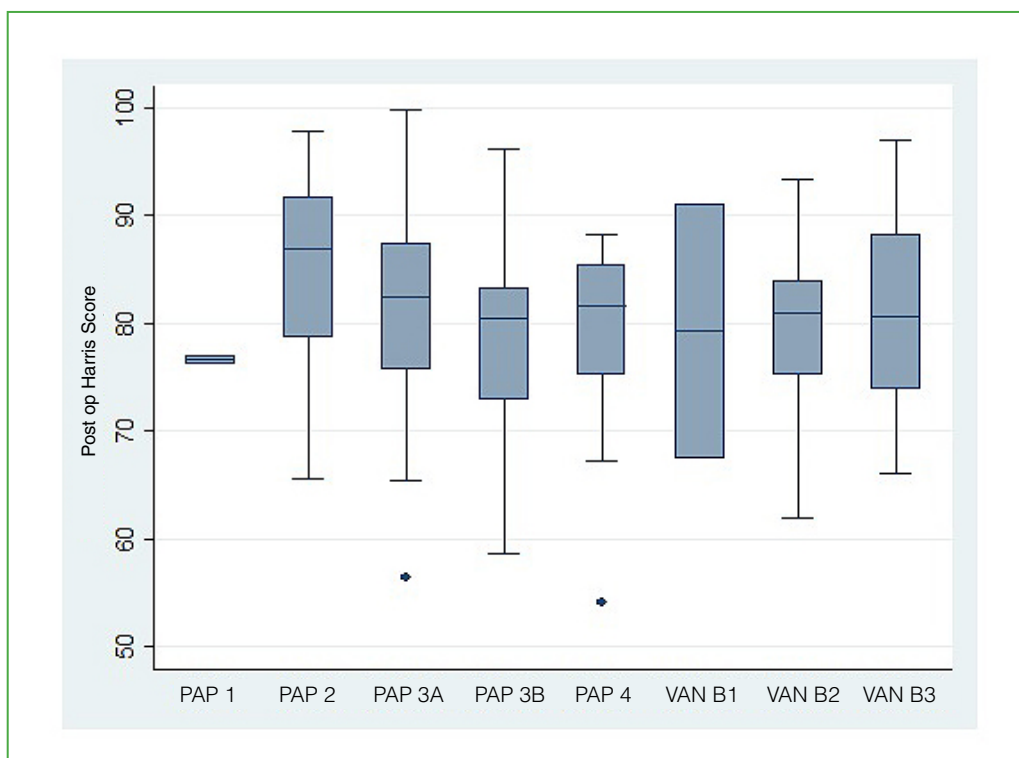
The bone stock deficit did not show statistically significant differences in relation to postoperative HHS ( $p = 0.086$ ). In contrast, patients with periprosthetic fractures tended towards lower HHS values.(Figure 5).

Only 14 patients required reoperations: five due to instability, where it was not necessary to revise the stem; four as a consequence of deep infection and five due to subsidence of the implant and aseptic loosening (at 5, 6, 7, 9 and 15 months, respectively).

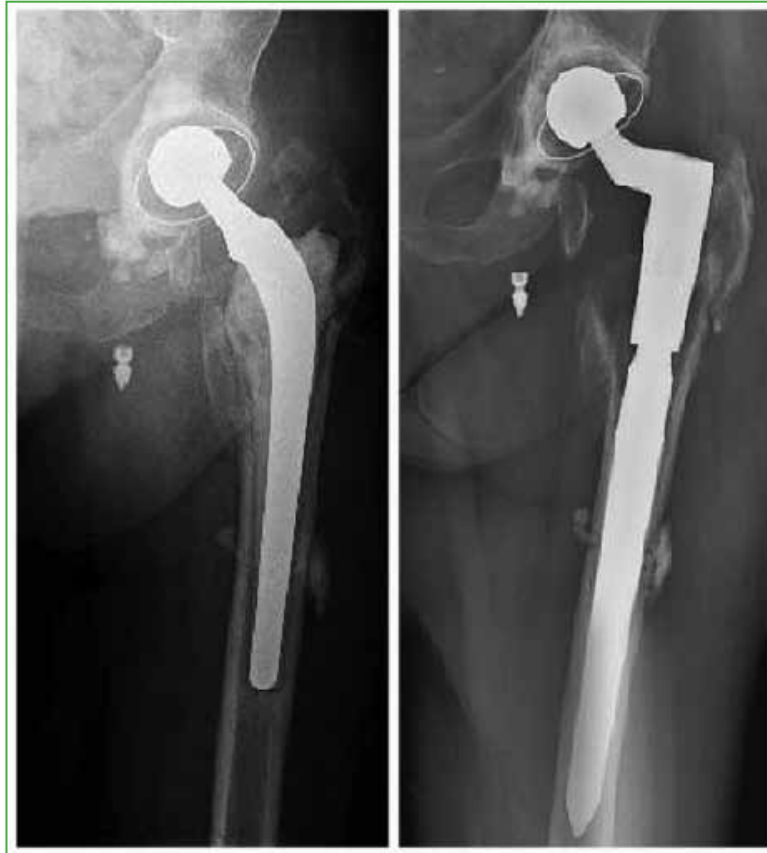At the end of follow-up, 95.05% of the patients included in this series had stable implants which did not require a new revision (Figures 6 and 7).



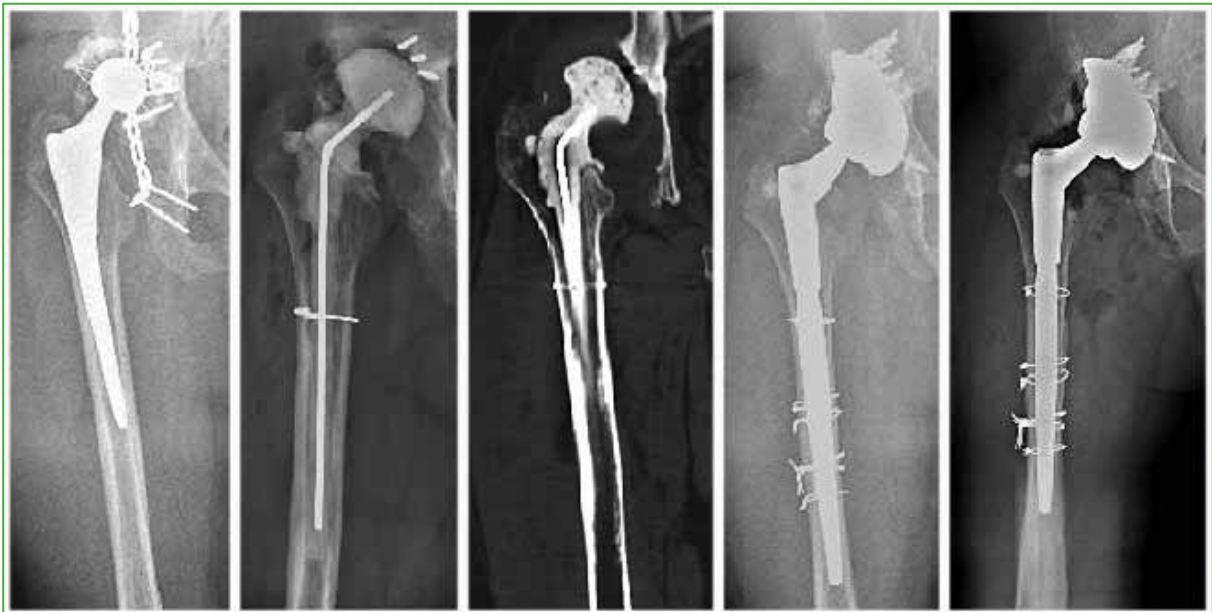**Figure 4.** Box plot of the follow-up time (months) according to sex, implant success, number of previous surgeries and causes of revision of the patients.



**Figure 5.** Box plot of the postoperative Harris Hip Score based on the classification of the implant placed. PAP = Paprosky, VAN = Vancouver.



**Figure 6.** 86-year-old woman. Aseptic loosening of the femoral stem. Femoral revision with distal fixation modular fluted tapered stem.



**Figure 7.** 35-year-old man. Sequela to acetabulum fracture plus avascular bone necrosis. Septic loosening. Cup revision plus trabecular metal augmentation and distal fixation modular fluted tapered stem.

## DISCUSSION

The revision of a total hip arthroplasty with bone stock deficiency is a challenge for any orthopedic surgeon. Modular fluted tapered stems offer several advantages, including axial and rotational stability, as well as modularity, protection against stress shielding, and a lower rate of intraoperative fractures and thigh pain, compared to cobalt-chrome stems with extensive porous coating.<sup>16-17,19,20,30</sup> The main challenge faced by the orthopedic surgeon when performing this type of surgery is to achieve a stable fixation of the femoral component. When the proximal femur is significantly compromised, either by fracture or bone stock deficit, femoral stabilization distal to the area of weakened bone is necessary for successful revision surgery.<sup>23</sup>

The success of modular fluted tapered stems has been reported in different studies<sup>22,30</sup> Our study included 182 patients, and it is one of the largest series reported.

In most published studies, implant survival without revision of the femoral component due to aseptic loosening is estimated to be 98% at 10 years.<sup>17,19</sup> In our cohort, at the end of follow-up, 95.05% had a stable implant without the need for a new surgery, even in those patients with severe bone stock deficits. This can be contrasted to most other femoral implant designs, such as extensively porous-coated cementless stems, whose success depends on the severity of bone loss.<sup>24</sup>

Abdel *et al.*<sup>31</sup> reported a 2.4% subsidence rate for implanted stems, and only one patient required reoperation. In our series, this complication was observed in 11.5% of the cases. However, when we analyzed the rest of the literature, the reported subsidence rate was similar to that of our series.<sup>19,28</sup> On the contrary, when the extensively porous-coated cobalt-chrome stems were analyzed, these values were higher.<sup>32</sup>

Klauser *et al.*<sup>33</sup> and Huang *et al.*<sup>34</sup> reported an intraoperative fracture rate of around 17%. In our study, only 2.19% (4 patients) had this complication.

In most published studies, the instability rate secondary to revision of the femoral component ranges from 2% to 21%.<sup>18,19</sup> In our series, it was 7.6%, which correlates with the published data.

Salcedo *et al.*<sup>35</sup> reported a 2.5% deep infection rate. Although infection can negatively affect implant survival, this complication is not frequent in most of the published series. In our study, only four patients required reoperation for this postoperative complication.

A limitation of our study is that it is a retrospective case series, not randomized and without a control group.

## CONCLUSIONS

The distal fixation modular fluted tapered stems provide a reproducible solution for the management of revisions of femoral components. In our series, this femoral revision technique achieved a high success rate with good functional results. The complication rate was similar to that reported in the literature. It is worth noting that preoperative planning and proper stem diameter selection are essential to avoid complications. However, a more extensive follow-up of patients is necessary to ensure that complications associated with modularity, such as corrosion, are not a problem in the future.

---

Conflict of interests: The authors declare they do not have any conflict of interests.

F. Vanoli ORCID ID: <https://orcid.org/0000-0002-5667-9716>

L. Pérez Alamino ORCID ID: <https://orcid.org/0000-0002-1563-6947>

I. Pioli ORCID ID: <https://orcid.org/0000-0001-8697-1980>

J. Gómez ORCID ID: <https://orcid.org/0000-0002-1162-2708>

F. A. Lopreite ORCID ID: <https://orcid.org/0000-0002-2065-8649>

P. Maletti ORCID ID: <https://orcid.org/0000-0001-5065-9880>

H. del Sel ORCID ID: <https://orcid.org/0000-0002-3655-1408>

B. L. Allende ORCID ID: <https://orcid.org/0000-0003-2757-4381>



## REFERENCES

1. Kurtz S, Ong K, Lau E, Mowat F, Halpern M. Projections of primary and revision hip and knee arthroplasty in the United States from 2005 to 2030. *J Bone Joint Surg Am* 2007;89(4):780-5. <https://doi.org/10.2106/JBJS.F.00222>
2. Gie GA, Linder L, Ling RS, Simon JP, Slooff TJ, Timperley AJ. Impacted cancellous allografts and cement for revision total hip arthroplasty. *J Bone Joint Surg Br* 1993;75(1):14-21. <https://doi.org/10.1302/0301-620X.75B1.8421012>
3. Engh CA, Glassman AH, Griffin WL, Mayer JG. Results of cementless revision for failed cemented total hip arthroplasty. *Clin Orthop Relat Res* 1988;(235):91-110. PMID: 3416544
4. Krishnamurthy AB, MacDonald SJ, Paprosky WG. 5- to 13-year follow-up study on cementless femoral components in revision surgery. *J Arthroplasty* 1997;12(8):839-47. [https://doi.org/10.1016/s0883-5403\(97\)90152-2](https://doi.org/10.1016/s0883-5403(97)90152-2)
5. Lawrence JM, Engh CA, Macalino GE, Lauro GR. Outcome of revision hip arthroplasty done without cement. *J Bone Joint Surg* 1994;76(7):965-73. <https://doi.org/10.2106/00004623-199407000-00002>
6. Wimmer MD, Randau TM, Deml MC, Ascherl R, Nöth U, Forst R, et al. Impaction grafting in the femur in cementless modular revision total hip arthroplasty: a descriptive outcome analysis of 243 cases with the MRP-TITAN revision implant. *BMC Musculoskelet Disord* 2013;14(1):19. <https://doi.org/10.1186/1471-2474-14-19>
7. Oshima S, Yasunaga Y, Yamasaki T, Yoshida T, Hori J, Ochi M. Midterm results of femoral impaction bone grafting with an allograft combined with hydroxyapatite in revision total hip arthroplasty. *J Arthroplasty* 2012;27(3):470-6. <https://doi.org/10.1016/j.arth.2011.07.012>
8. Ten Have BLEF, Brouwer MD RW, van Biezen FC, Verhaar JAN. Femoral revision surgery with impaction bone grafting: 31 hips followed prospectively for ten to 15 years. *J Bone Joint Surg Br* 2012;94(5):615-8. <https://doi.org/10.1302/0301-620X.94B5.27909>
9. Mulroy WF, Harris WH. Revision total hip arthroplasty with use of so-called second-generation cementing techniques for aseptic loosening of the femoral component. A fifteen-year-average follow-up study. *J Bone Joint Surg* 1996;78(3):325-30. <https://doi.org/10.2106/00004623-199603000-00002>
10. Davis CM, Berry DJ, Harmsen WS. Cemented revision of failed uncemented femoral components of total hip arthroplasty. *J Bone Joint Surg Am* 2003;85(7):1264-9. <https://doi.org/10.2106/00004623-200307000-00012>
11. Lin Min, Jing Peng, Hong Duan, Wenli Zhang, Yong Zhou, Chongqi Tu. Uncemented allograft-prosthetic composite reconstruction of the proximal femur. *Indian J Orthop* 2014;48(3):289-95. <https://doi.org/10.4103/0019-5413.132521>
12. Mayle Jr RE, Paprosky WG. Massive bone loss: Allograft-prosthetic composites and beyond. *J Bone Joint Surg Br* 2012;94(11 Suppl A):61-4. <https://doi.org/10.1302/0301-620X.94B11.30791>
13. Kato T, Otani T, Sugiyama H, Hayama T, Katsumata S, Marumo K. Cementless total hip arthroplasty in hip dysplasia with an extensively porous-coated cylindrical stem modified for Asians: A 12-year follow-up study. *J Arthroplasty* 2015;30(6):1014-8. <https://doi.org/10.1016/j.arth.2015.01.033>
14. Shen B, Huang Q, Yang J, Zhou Z, Kang P, Pei F. Extensively coated non-modular stem used in two-stage revision for infected total hip arthroplasty: Mid-term to long-term follow-up: non-modular stem for infected THA. *Orthop Surg* 2014;6(2):103-9. <https://doi.org/10.1111/os.12107>
15. Thomsen PB, Jensen NJF, Kampmann J, Hansen TB. Revision hip arthroplasty with an extensively porous-coated stem - Excellent long-term results also in severe femoral bone stock loss. *Hip Int* 2013;23(4):352-8. <https://doi.org/10.5301/hipint.5000032>
16. Abdel MP, Lewallen DG, Berry DJ. Periprosthetic femur fractures treated with modular fluted, tapered stems. *Clin Orthop Relat Res* 2014;472(2):599-603. <https://doi.org/10.1007/s11999-013-2936-4>
17. Van Houwelingen AP, Duncan CP, Masri BA, Greidanus NV, Garbuz DS. High survival of modular tapered stems for proximal femoral bone defects at 5 to 10 years followup. *Clin Orthop Relat Res* 2013;471(2):454-62. <https://doi.org/10.1007/s11999-012-2552-8>
18. Amanatullah DF, Howard JL, Siman H, Trousdale RT, Mabry TM, Berry DJ. Revision total hip arthroplasty in patients with extensive proximal femoral bone loss using a fluted tapered modular femoral component. *Bone Joint Br* 2015;97(3):312-7. <https://doi.org/10.1302/0301-620X.97B3.34684>
19. Rodriguez JA, Deshmukh AJ, Robinson J, Cornell CN, Rasquinha VJ, Ranawat AS, et al. Reproducible fixation with a tapered, fluted, modular, titanium stem in revision hip arthroplasty at 8–15 years follow-up. *J Arthroplasty* 2014;29(9):214-8. <https://doi.org/10.1016/j.arth.2013.12.035>
20. Munro JT, Garbuz DS, Masri BA, Duncan CP. Tapered fluted titanium stems in the management of Vancouver B2 and B3 periprosthetic femoral fractures. *Clin Orthop Relat Res* 2014;472(2):590-8. <https://doi.org/10.1007/s11999-013-3087-3>

21. Abdel MP. CORR Insights®: Can a conical implant successfully address complex anatomy in primary THA? Radiographs and hip scores at early followup. *Clin Orthop Relat Res* 2016;474(2):465-6. <https://doi.org/10.1007/s11999-015-4530-4>
22. Park M-S, Lee J-H, Park J-H, Ham D-H, Rhee Y-K. A distal fluted, proximal modular femoral prosthesis in revision hip arthroplasty. *J Arthroplasty* 2010;25(6):932-8. <https://doi.org/10.1016/j.arth.2009.06.031>
23. Sculco PK, Abdel MP, Hanssen AD, Lewallen DG. The management of bone loss in revision total knee arthroplasty: rebuild, reinforce, and augment. *Bone Joint J* 2016;98-B(1 Suppl A):120-4. <https://doi.org/10.1302/0301-620X.98B1.36345>
24. Paprosky WG, Burnett RSJ. Assessment and classification of bone stock deficiency in revision total hip arthroplasty. *Am J Orthop (Belle Mead NJ)* 2002;31(8):459-64. PMID: 12216969
25. Ling RS, Timperley AJ, Linder L. Histology of cancellous impaction grafting in the femur. A case report. *J Bone Joint Surg Br* 1993;75(5):693-6. <https://doi.org/10.1302/0301-620X.75B5.8376422>
26. Duncan CP, Masri BA. Fractures of the femur after hip replacement. *Instr Course Lect* 1995;44:293-304. PMID: 7797866
27. Callaghan JJ, Salvati EA, Pellicci PM, Wilson PD Jr, Ranawat CS. Results of revision for mechanical failure after cemented total hip replacement. 1979 to 1982. A two to five-year follow-up. *J Bone Joint Surg Am* 1985;67:1074-85. PMID: 4030826
28. Park M-S, Lim Y-J, Chung W-C, Ham D-H, Lee S-H. Management of periprosthetic femur fractures treated with distal fixation using a modular femoral stem using an anterolateral approach. *J Arthroplasty* 2009;24(8):1270-6. <https://doi.org/10.1016/j.arth.2009.07.013>
29. Harris WH. Traumatic arthritis of the hip after dislocation and acetabular fractures: treatment by mold arthroplasty. An end-result study using a new method of result evaluation. *J Bone Joint Surg Am* 1969;51(4):737-55. PMID: 5783851
30. Fink B, Urbansky K, Schuster P. Mid term results with the curved modular tapered, fluted titanium Revitan stem in revision hip replacement. *Bone Joint J* 2014;96-B(7):889-95. <https://doi.org/10.1302/0301-620X.96B7.33280>
31. Abdel MP, Cottino U, Larson DR, Hanssen AD, Lewallen DG, Berry DJ. Modular fluted tapered stems in aseptic revision total hip arthroplasty. *J Bone Joint Surg* 2017;99(10):873-81. <https://doi.org/10.2106/JBJS.16.00423>
32. Garcia-Cimbrelo E, Garcia-Rey E, Cruz-Pardos A, Madero R. Stress-shielding of the proximal femur using an extensively porous-coated femoral component without allograft in revision surgery: a 5- to 17-year follow-up study. *J Bone Joint Surg Br* 2010;92(10):1363-9. <https://doi.org/10.1302/0301-620X.92B10.24317>
33. Klauser W, Bangert Y, Lubinus P, Kendoff D. Medium-term follow-up of a modular tapered noncemented titanium stem in revision total hip arthroplasty: a single-surgeon experience. *J Arthroplasty* 2013;28(1):84-9. <https://doi.org/10.1016/j.arth.2012.07.001>
34. Huang Y, Shao H, Zhou Y, Gu J, Tang H, Yang D. Femoral bone remodeling in revision total hip arthroplasty with use of modular compared with monoblock tapered fluted titanium stems: the role of stem length and stiffness. *J Bone Joint Surg Am* 2019;101(6):531-8. <https://doi.org/10.2106/JBJS.18.00442>
35. Salcedo Zunino LA, Núñez J, Mangupli MM, Pioli I, Gomez J, Allende BL. Revisión femoral con tallo cónico de fijación distal. *Rev Asoc Argent Ortop Traumatol* 2017;82(1):40-2. <https://www.aoot.org.ar/revista/2017/n1/7.pdf>