

# Mazabraud Syndrome: A Case Report

Rodrigo Re,<sup>\*</sup> Maximiliano Negri,<sup>\*\*</sup> Jorge Flores<sup>#</sup>

<sup>\*</sup> Diagnostic Imaging Service, Osteoarticular / Musculoskeletal Area - Interventionism, Sanatorio Allende (Córdoba, Argentina)

<sup>\*\*</sup> Traumatology Service, Sanatorio Allende (Córdoba, Argentina)

<sup>#</sup> Pathological Anatomy Service, Sanatorio Allende (Córdoba, Argentina)

## ABSTRACT

Mazabraud's Syndrome is a rare association of lesions to the musculoskeletal system. It results from the combination of one or more intramuscular myxomas and fibrous dysplasia. We present a case of a 46-year-old man with bone lesions compatible with fibrous dysplasia associated with intramuscular myxoma, configuring Mazabraud's Syndrome, and a review of the literature.

**Keywords:** Mazabraud's syndrome; fibrous dysplasia; intramuscular myxoma.

**Level of Evidence:** IV

## Síndrome de Mazabraud: reporte de un caso

## RESUMEN

El síndrome de Mazabraud es una rara asociación de lesiones del sistema musculoesquelético. Resulta de la combinación de uno o varios mixomas intramusculares y displasia fibrosa. Presentamos a un hombre de 46 años con lesiones óseas compatibles con displasia fibrosa asociada a mixoma intramuscular configurando un síndrome de Mazabraud y una revisión de la bibliografía.

**Palabras clave:** Síndrome de Mazabraud; displasia fibrosa; mixoma intramuscular.

**Nivel de Evidencia:** IV

## INTRODUCTION

Fibrous dysplasia is a developmental skeletal abnormality of unknown etiology; it is characterized by the replacement of the medullary cavity by fibrous tissue. It can present as a single lesion (monostotic) or multiple lesions (polyostotic).<sup>1</sup> It produces bone fragility with deformity, pain, pathological fractures, and functional impairment. Fibrous dysplasia is usually located in the pelvis and femur. On radiographs, it is visualized as lytic or dense diaphyseal-metaphyseal lesions, localized or diffuse, which can expand the bone and generate a trabeculated appearance, like "ground glass".<sup>2</sup>

The association between fibrous dysplasia and intramuscular myxomas is called Mazabraud syndrome. The first case was described by Henschen in 1926<sup>3</sup> and named by Mazabraud in 1957.<sup>4</sup> Approximately 100 cases have been reported to date.<sup>1</sup>

Intramuscular myxoma is a rare lesion, with difficult radiological and clinical diagnosis. Its incidence is 1:1,000,000. It is a benign soft tissue neoplasm of mesenchymal origin.<sup>5</sup> It typically involves muscles, thighs, buttocks, shoulders, and the upper arm. Clinically, intramuscular myxomas present as a slow-growing, ovoid, painless mass.<sup>6-9</sup>

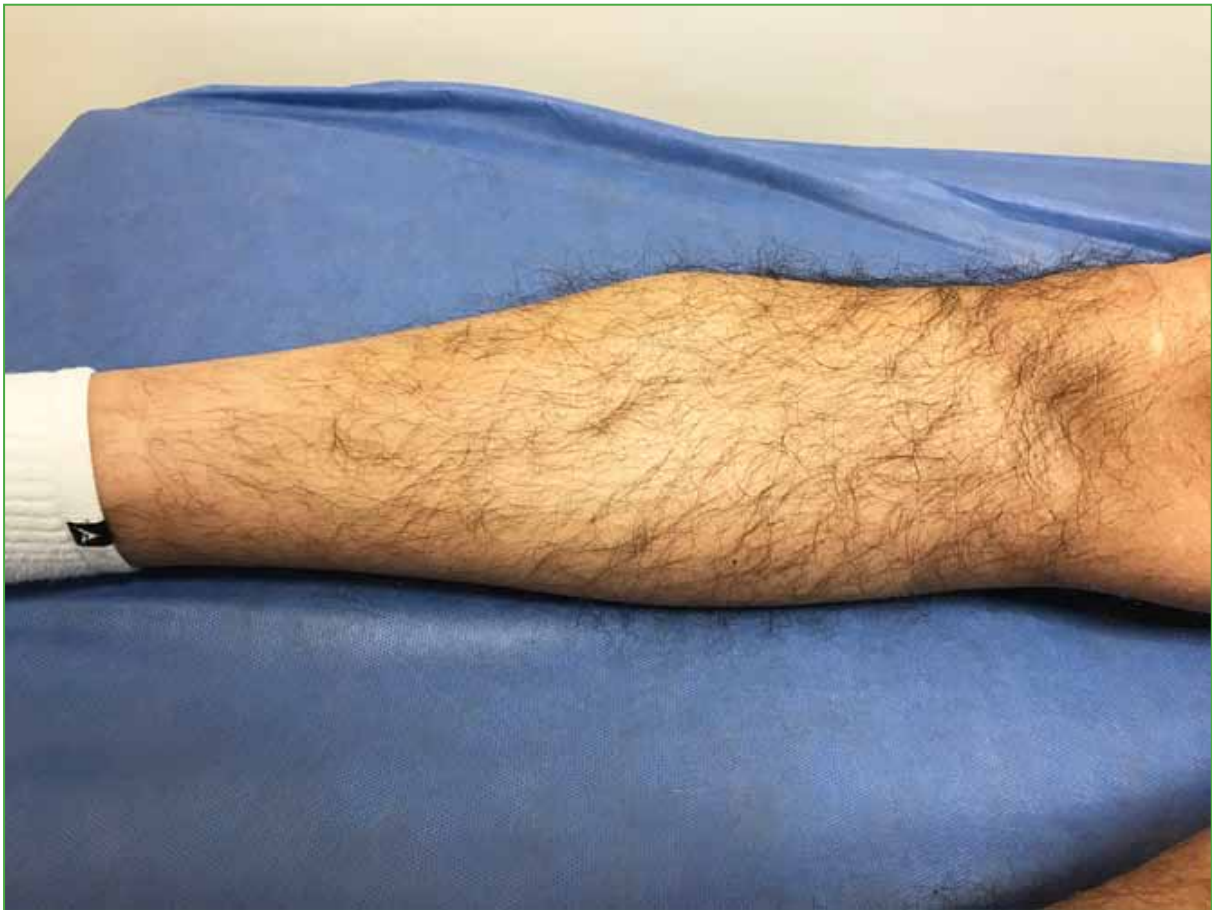## CLINICAL CASE

A 46-year-old man, with no pathological history, who consulted a general practitioner in another center, in October 2019, for localized mechanical low back pain during physical activity, of several months of evolution. An MRI of the spine and pelvis was requested, in which a doubtful image was observed in the proximal femur, so it was decided to extend the study to the thigh and complement it with radiographs and computed tomography of the entire right lower limb.

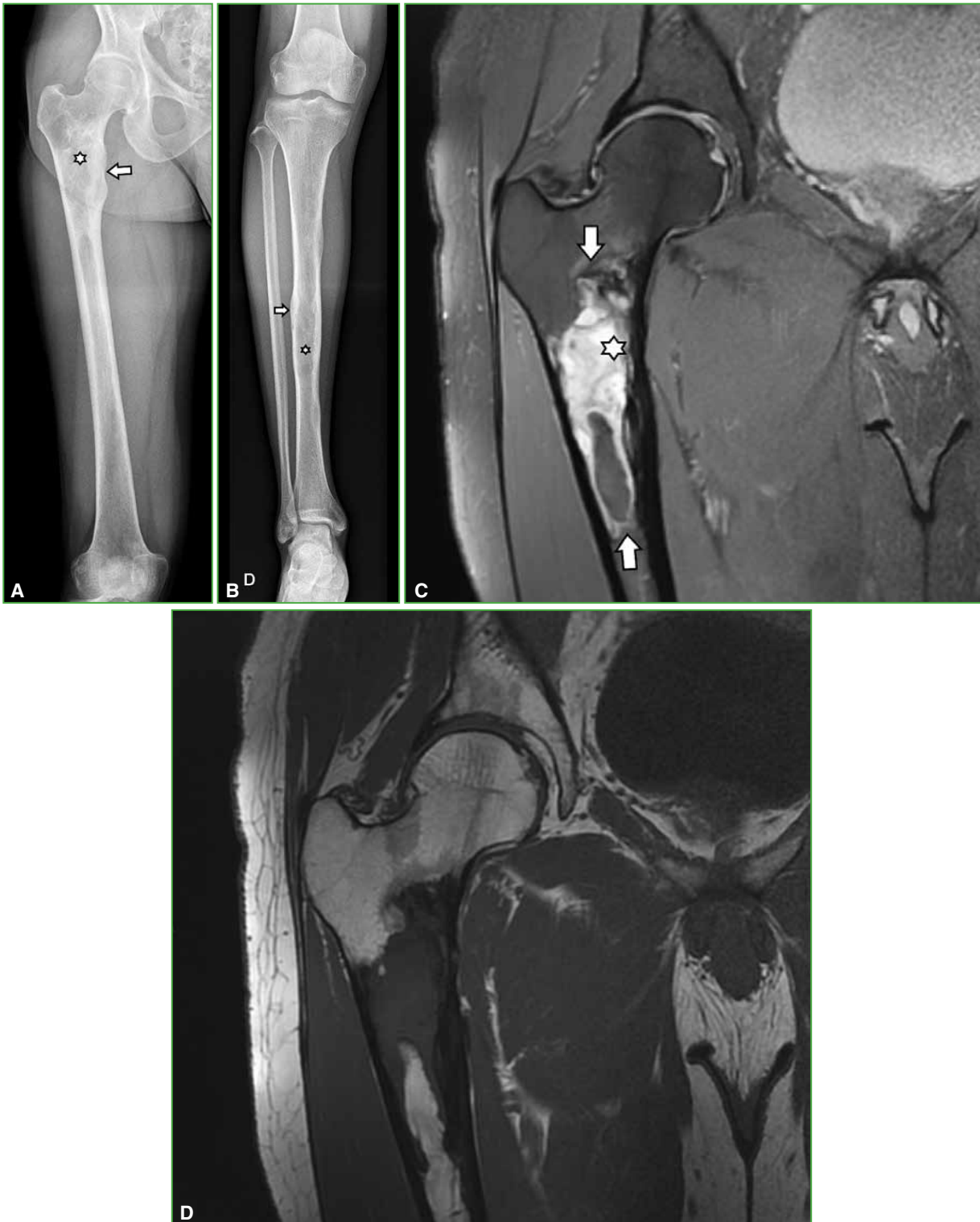
Received on April 14th, 2020. Accepted after evaluation on May 4th, 2020 • RODRIGO RE, MD • rodrigo\_re@hotmail.com  <https://orcid.org/0000-0001-7382-9459>

**How to cite this article:** Re R, Negri M, Flores J. Mazabraud Syndrome: A Case Report. *Rev Asoc Argent Ortop Traumatol* 2021;86(3):XXXX. <https://doi.org/10.15417/issn.1852-7434.2021.86.3.1102>

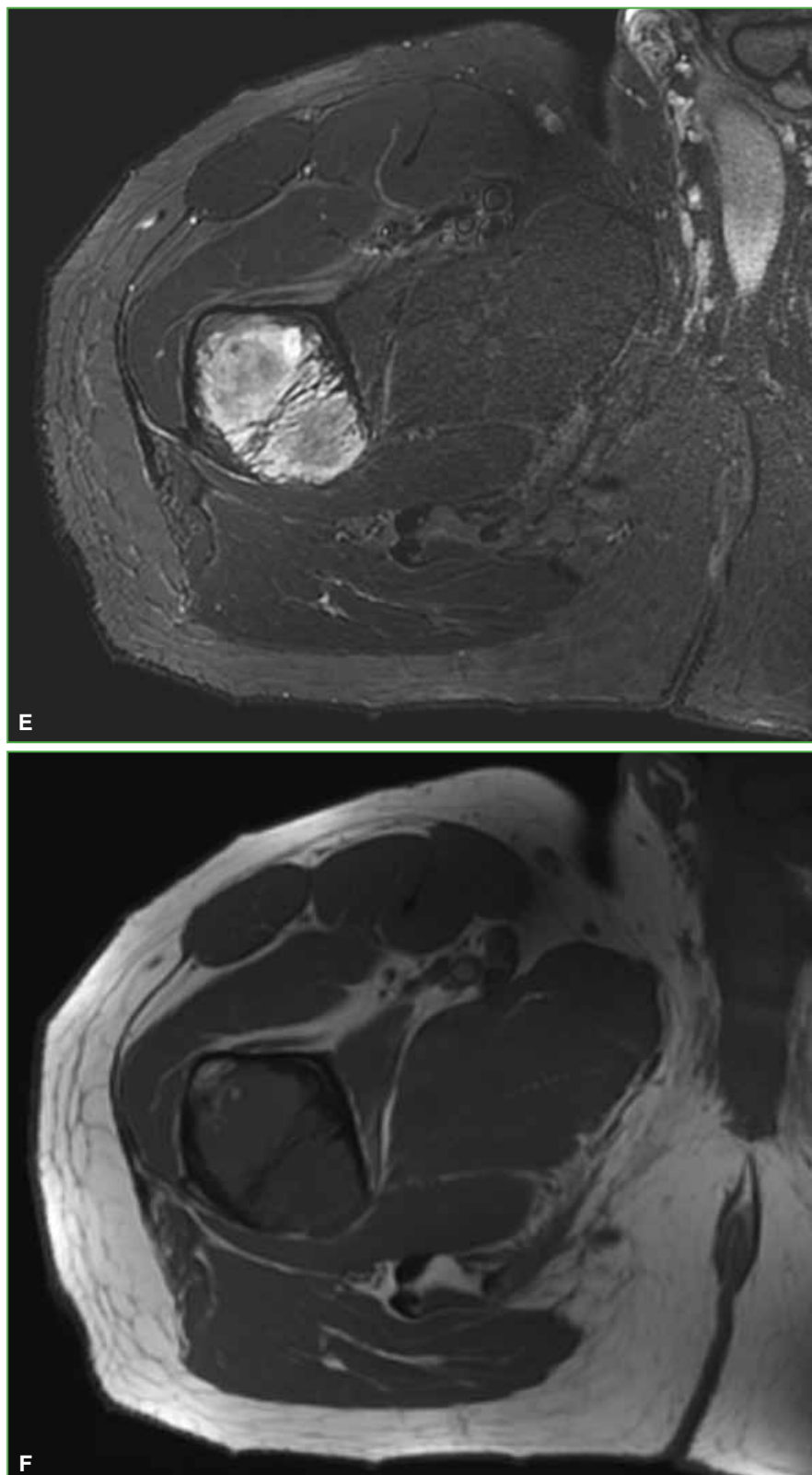
In February 2020, the patient consulted a traumatologist at our center. On physical examination, full range of motion of the hip and knee was observed, with no pain in the right lower limb. In addition, a tumor was palpated in the proximal anterolateral area of the right leg, of approximately 8 cm, deep, elastic, not painful (Figure 1). The patient expressed that he had had the tumor since the age of 17 and its growth had been slow. New radiographs and an MRI of the hip and leg were requested, as well as an ultrasound of the soft tissue mass in the leg (Figure 2).



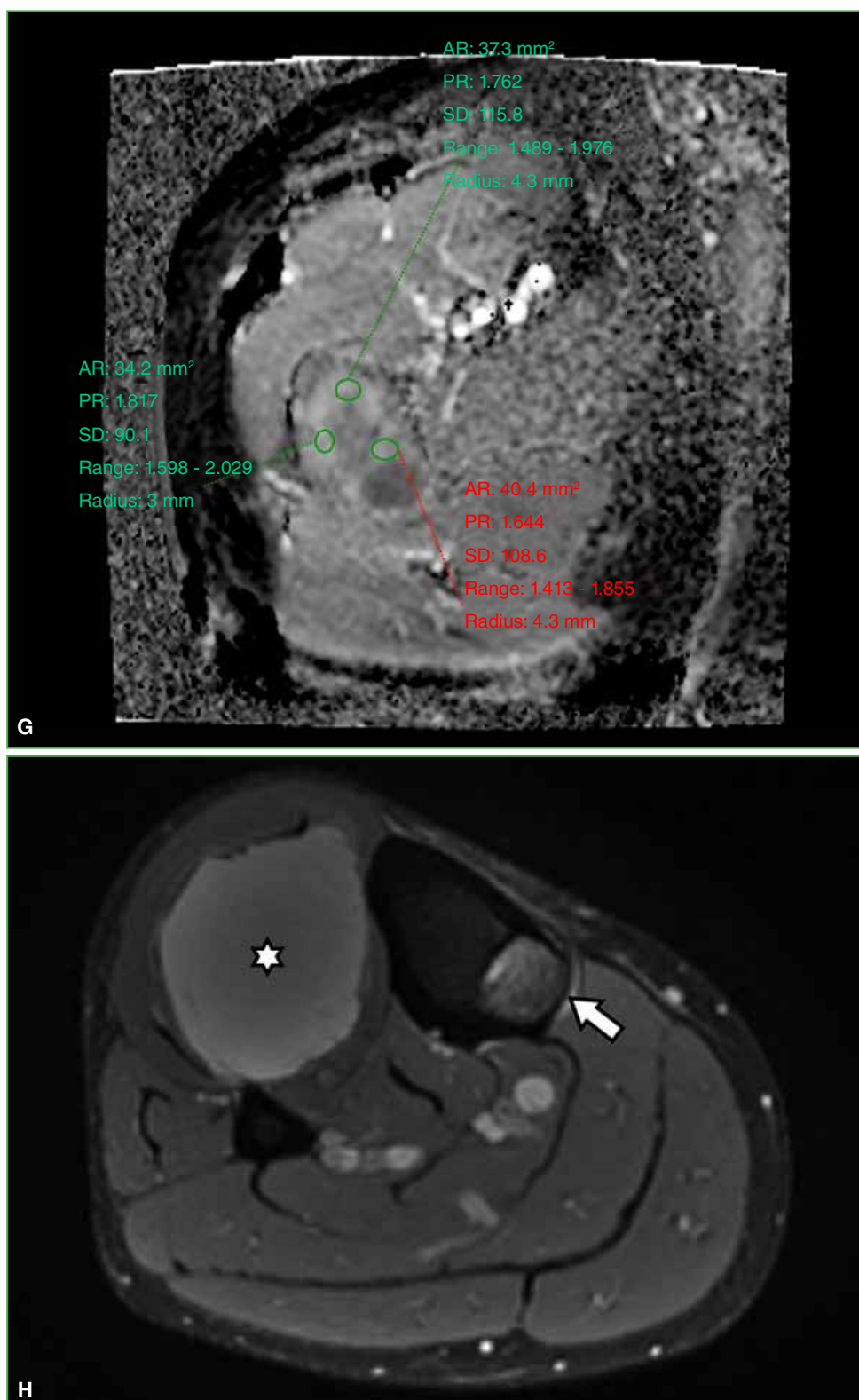
**Figure 1.** Clinical image of the lesion.



**Figure 2.** **A.** Frontal radiograph of the right femur. Bulging (asterisk) of the femoral neck adjacent to the lesser trochanter, cortical thinning (arrow), with loss of trabecular pattern. **B.** Radiograph of the right leg showing three lesions with similar characteristics to those described in the femur, endosteal involvement (arrow) and “ground glass” appearance (asterisk). **C.** Right hip MRI, coronal plane, STIR sequence. Marked hypersignal, endosteal compromise (asterisk), bone bulging and defined limits (arrows). **D.** Right hip MRI, coronal plane, T1-weighted sequence with marked hyposignal.

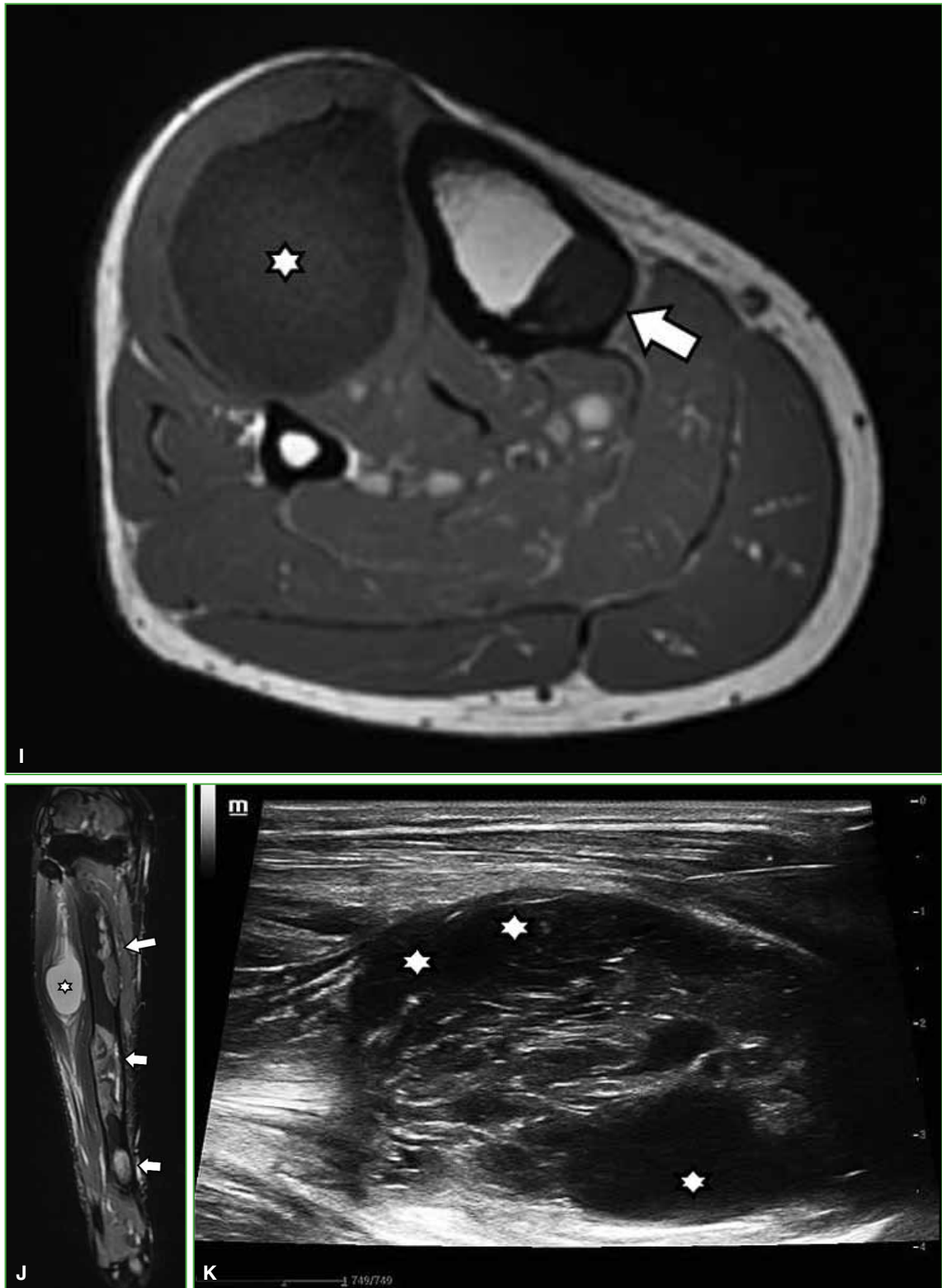


**Figure 2.** E. Right hip MRI, axial plane, STIR sequence with hypersignal. Bone bulging and thin interior septa. F. Right hip MRI, axial plane, T1-weighted sequence with hyposignal.



**Figure 2.** **G.** Map of the apparent diffusion coefficient with an average value of  $1.7 \times 10^{-3} \text{ mm}^2/\text{s}$ , marking a facilitated diffusion. **H.** Right leg MRI, axial plane, STIR sequence. Hyperintense lesion in the proximal tibia (arrow) and markedly hyperintense lesion in soft tissue, in the anteroexternal muscle plane (asterisk).

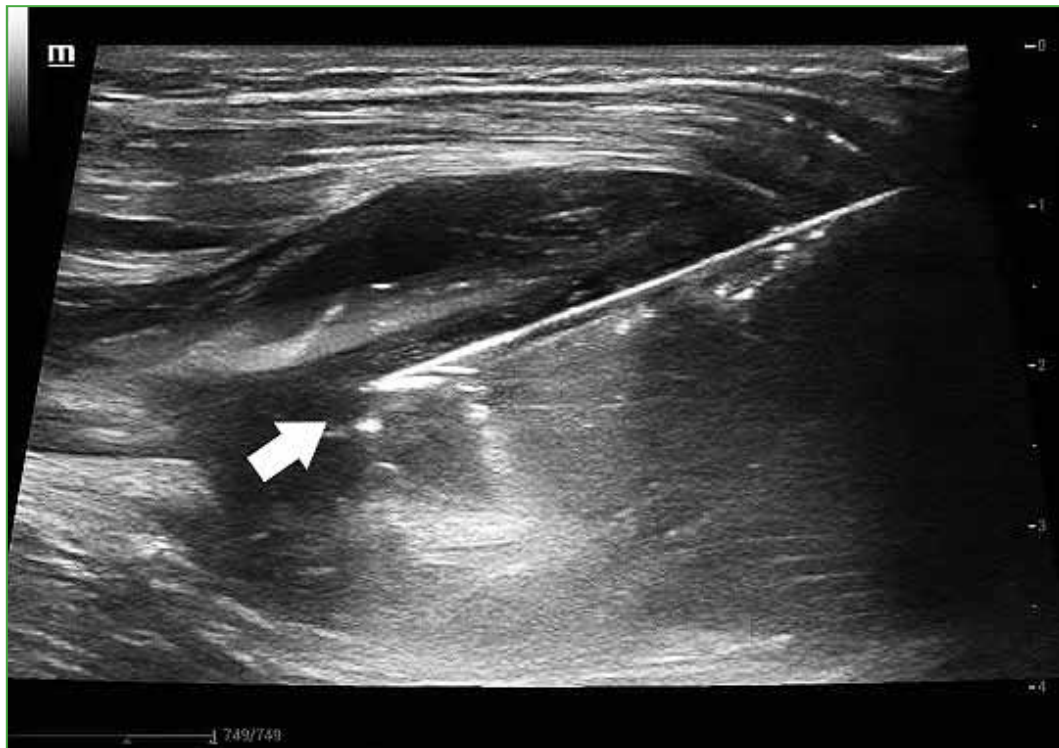



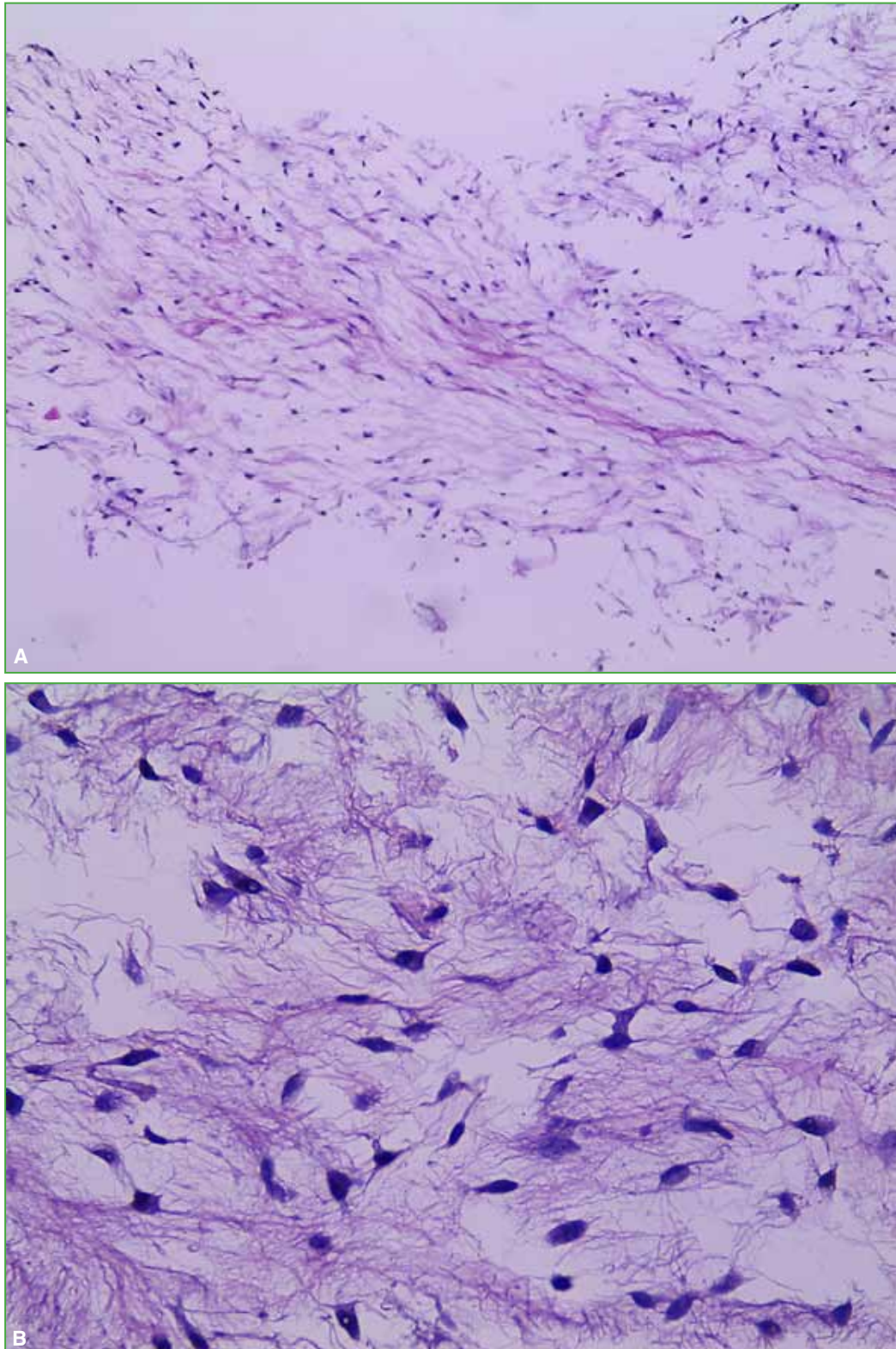
**Figure 2.** **I.** Right leg MRI, axial plane, T1-weighted sequence. Hypointense lesion in the proximal tibia (arrow) and markedly hypointense lesion in soft tissue (asterisk). **J.** Right leg MRI, coronal plane, STIR sequence. Multiple hyperintense bone lesions (arrows) and hyperintense soft tissue lesions (asterisk). **K.** Ultrasound of the soft tissue injury. Ovoid morphology, with partially defined borders, heterogeneous, with small peripheral cystic areas (asterisks).

Given the suspicion of an association between bone lesions, interpreted as fibrous dysplasia and soft tissue lesion, a biopsy of the soft tissue mass was requested (Figure 3). The histological analysis confirmed the intramuscular myxoma (Figure 4), which configures a Mazabraud syndrome.

The patient will continue under observation with radiological and clinical evolution studies.



**Figure 3.** Ultrasound-guided cutting-needle biopsy of the soft tissue lesion (arrow).



**Figure 4.** Pathological anatomy analysis with hematoxylin-eosin staining. Medium (A) and high magnification (B). A mesenchymal tumor with spindle cell myxoid stroma is seen. There are no atypia, mitosis, necrosis, or other significant alterations.



## DISCUSSION

Fibrous dysplasia is a rare benign lesion caused by a genetic mutation in the GNAS gene, located in chromosome 20q13.2-q13.3.<sup>10</sup> It is characterized by the presence of non-ossified areas in the bone. It can be monostotic or polyostotic, and is more common in women (68%).<sup>1,2,10</sup> In general, it is diagnosed between the first and third decade of life. The most affected sites are the proximal femur, tibia, skull, ribs and, to a lesser extent, the humerus, forearm and pelvis. Often there are several conditions in the same bone.

The monostotic variant has an asymptomatic presentation; it appears as an incidental finding. The polyostotic variant can present with intermittent pain, stress fractures, expansion masses in palpable bones, or pathological fractures. The association of polyostotic fibrous dysplasia with intramuscular myxoma configures Mazabraud syndrome.<sup>1,2,9,10</sup>

Imaging of fibrous dysplasia is important for proper diagnosis and follow-up, to detect and treat possible complications.

On radiographs, it is visualized as radiolucent intramedullary diaphyseal lesions with a “ground glass” appearance and loss of the normal trabecular pattern, endosteal compromise and cortical thinning with spared areas. The margins are defined. A periosteal reaction is not observed. Computed tomography images confirm the presence of homogeneous lesions with a “ground glass” appearance. There may be cystic areas and calcifications. On magnetic resonance imaging, lesions with low signal on T1-weighted sequences and high signal on T2-weighted sequences are observed. There may be a hypointense halo around it in the T1- and T2-weighted sequences. As it is a benign lesion, it has facilitated diffusion with apparent diffusion coefficient values above  $1.1 \times 10^{-3} \text{ mm}^2 / \text{s}$ .<sup>1,2,10</sup>

Radiographs are normal, although intramuscular myxomas may present with non-specific soft tissue calcifications. On ultrasound, intramuscular myxomas are visualized as ovoid masses, poorly defined and hypoechoic, with possible cystic areas. On computed tomography, they appear as hypointense lesions with a wall that separates them from muscle tissue. On MRI, they are visualized as hyperintense lesions on T2-weighted, gradient echo, or STIR sequences. T1-weighted sequences show low signal.<sup>2,6-9</sup>

## CONCLUSIONS

Although the association between fibrous dysplasia and intramuscular myxomas is rare, it is probably underestimated due to misdiagnosis. Fibrous dysplasia is usually diagnosed earlier than intramuscular myxomas or at the same time, as findings on routine radiographs or MRI.

Symptoms are rare, they can manifest as pathological fractures or palpable masses.

The treatment of intramuscular myxomas is surgical excision. Fibrous dysplasia is controlled with imaging tests. The possibility of malignant transformation is low.

Conflict of interests: The authors declare they do not have any conflict of interests.

M. Negri ORCID ID: <https://orcid.org/0000-0002-7512-8418>

J. Flores ORCID ID: <https://orcid.org/0000-0002-8883-3650>

## REFERENCES

1. Vescini F, Falchetti A, Tonelli V, Carpentieri M, Cipri C, Cosso R, et al. Mazabraud's syndrome: a case report and up-to-date literature review. *Endocr Metab Immune Disord Drug Targets* 2019;19(6):885-93. <https://doi.org/10.2174/1871530319666181226103700>
2. Case DB, Chapman CN Jr, Freeman JK, Polga JP. Atypical presentation of polyostotic fibrous dysplasia with myxoma (Mazabraud syndrome). *RadioGraphics* 2010;30:827-32. <https://doi.org/10.1148/rg.303095155>
3. Henschen F. Fall von ostitis Fibrosa mit multiplen Tumoren in derumgebenden Muskulatur. *Verh Dtsch Ges Pathol* 1926;21:93-7.

4. Mazabraud A, Girard J. [A peculiar case of fibrous dysplasia with osseous and tendinous localizations]. *Rev Rhum Mal Osteoartic* 1957;24(9-10):652-9. PMID: 13518962
5. Stout A. Myxoma: the tumor of primitive mesenchyme. *Ann Surg* 1948;127(4):706-19. PMID: 18917127
6. Nielsen GP, O'Connell JX, Rosenberg AE. Intramuscular myxoma: a clinicopathologic study of 51 cases with emphasis on hypercellular and hypervascular variants. *Am J Surg Pathol* 1998;22(10):1222-7. <https://doi.org/10.1097/00000478-199810000-00007>
7. Murphey MD, McRae GA, Fanburg-Smith JC, Levine AM, Aboulaia AJ. Imaging of soft-tissue myxoma with emphasis on CT and MR and comparison of radiologic and pathologic findings. *Radiology* 2002;225(1):215-24. <https://doi.org/10.1148/radiol.2251011627>
8. Nishio J, Naito M. FDG PET/CT and MR imaging of intramuscular myxoma in the gluteus maximus. *World J Surg Oncol* 2012;10(1):132. <https://doi.org/10.1186/1477-7819-10-132>
9. Baltu Y, Arikan ŞM, Dölen UC, Uzun H, Alkan Bİ, Aydın O. Intramuscular myxoma: clinical and surgical observation notes on eleven cases. *Int Orthop* 2017;41(4):837-43. <https://doi.org/10.1007/s00264-016-3396-8>
10. Zoccali C, Teori G, Prencipe U, Erba F. Mazabraud's syndrome: A new case and review of the literature. *Int Orthop* 2009;33(3):605-10. <https://doi.org/10.1007/s00264-007-0483-x>