

# Pure Medial Subtalar Dislocation: Case Report and Literature Review

Marcos R. Latorre, Javier E. Sánchez Saba, Mariano O. Abrego, Fernando Díaz Dileria, Franco L. De Cicco, Facundo Bilbao

Orthopedics and Traumatology Department, Hospital Italiano de Buenos Aires, Ciudad Autónoma de Buenos Aires, Argentina

## ABSTRACT

Isolated subtalar dislocations without associated fractures are a rare entity. They represent only 1% of dislocations in humans. We present a series of 3 cases of pure medial dislocations in patients who suffered high-energy trauma. In all cases, the treatment was closed reduction under anesthesia and subsequent immobilization; all with good results. Subtalar dislocations require early diagnosis and rapid resolution. The aim of this presentation is to demonstrate the importance of diagnostic suspicion and the benefit of early treatment for successful outcomes.

**Key words:** Subtalar dislocation; complications; closed reduction.

**Level of Evidence:** IV

## Luxación periastragalina medial pura: reporte de casos y revisión bibliográfica.

## RESUMEN

Las luxaciones subastragalinas (periastragalinas) sin fractura asociada son un cuadro poco frecuente. Representan solo el 1% de las luxaciones en el ser humano. Presentamos tres casos de luxaciones mediales puras en pacientes que sufrieron un traumatismo de alta energía. En todos los casos, el tratamiento consistió en la reducción cerrada bajo anestesia y posterior inmovilización; la evolución fue satisfactoria. Las luxaciones subastragalinas requieren de un diagnóstico temprano y una rápida resolución. Con estos casos se quiere demostrar la importancia de la sospecha diagnóstica y el beneficio de un tratamiento precoz y acertado.

**Palabras clave:** Luxación periastragalina; complicaciones; reducción cerrada.

**Nivel de Evidencia:** IV

## INTRODUCTION

Subtalar dislocations are often associated to talar, malleolar or even metatarsal fractures.<sup>1</sup> Pure dislocations are rare, in part due to the presence of strong ligament structures, well adapted to bear the weight, such as the talocalcaneal ligament and the cervical ligament. The main cause of this injury is high-energy trauma.<sup>2</sup> The mechanics of the injury consist of a forced inversion of the forefoot when the foot is in a plantar flexion. Malgaigne et al.<sup>3</sup> described four variants: lateral, anterior, posterior and medial, the latter being the most frequent. Medial dislocations represent up to 85% of cases.<sup>4</sup> Both the talocalcaneal and calcaneonavicular joints are compromised. However, the calcaneocuboid and talotibial joints are usually not affected.<sup>5</sup> Our aim is to communicate three cases of pure subtalar dislocation (without associated fractures) and to review literature on the topic.

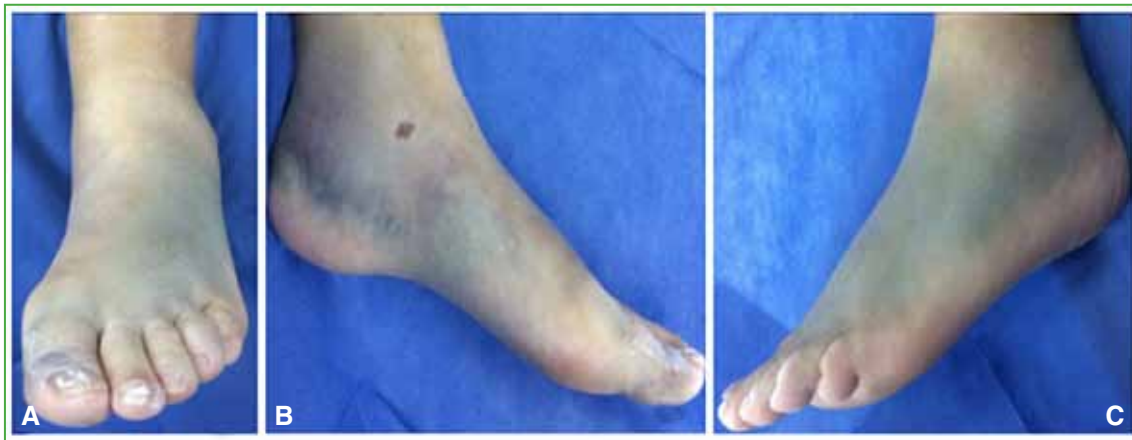Received on April 4<sup>th</sup>, 2020. Accepted after evaluation on June 22<sup>nd</sup>, 2020 • MARCOS R. LATORRE, MD • marcos.latorre@hospitalitaliano.org.ar

 <https://orcid.org/0000-0002-2172-2542>

**How to cite this paper:** Latorre MR, Sánchez Saba JE, Abrego MO, Díaz Dileria F, De Cicco FL, Bilbao F. Pure Medial Subtalar Dislocation: Case Report and Literature Review. *Rev Asoc Argent Ortop Traumatol* 2021;86(1):83-90. <https://doi.org/10.15417/issn.1852-7434.2021.86.1.1099>

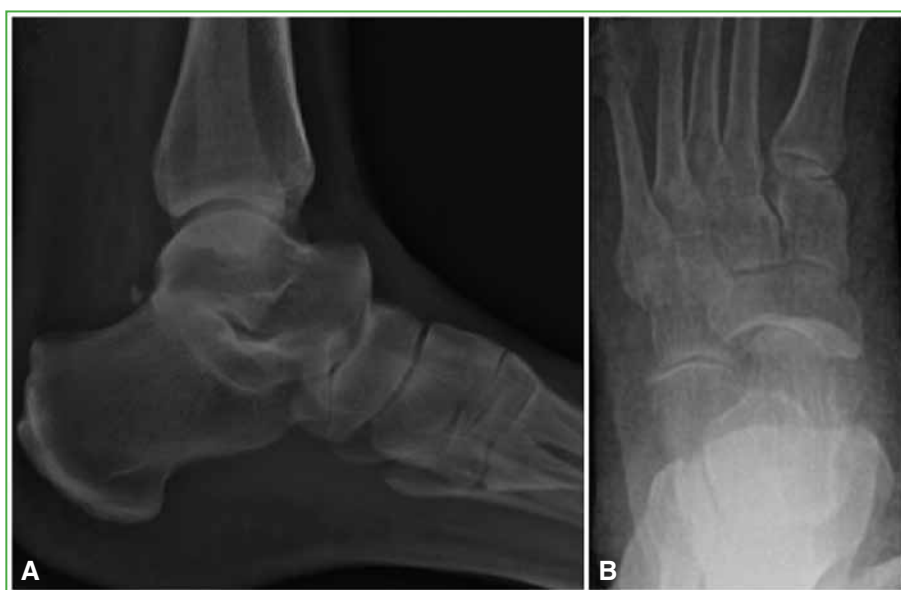## CLINICAL CASE 1

A 69-year-old woman without relevant medical history attended the ER after suffering high-energy trauma as a result of being rammed by a car. She indicated pain related to the functional impairment of the left foot and ankle. She had first been assisted in a different ER, where she was immobilized with a short leg plaster cast to aid in pain management, but without a conclusive diagnosis. Within the first 24 hours of the injury, she attended our facilities due to persistent pain. She was assisted in an urgent manner. As a first measure, her cast was removed to inspect the skin and soft tissue. The patient suffered from intense pain in her left foot and ankle as a result of edema and bruising. (Figure 1)

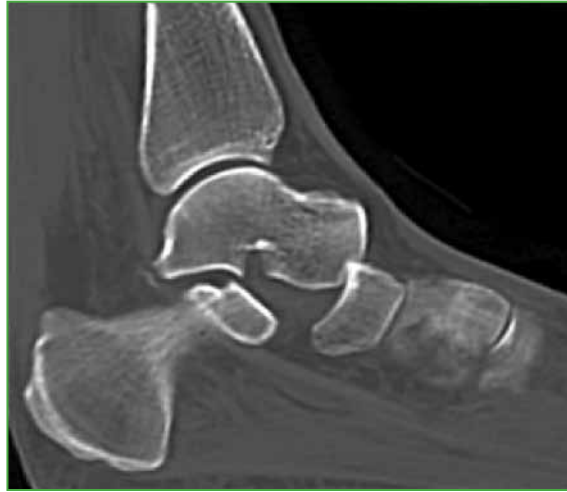

**Figure 1.** Clinical images of the affected soft tissue and the foot in a plantar flexion with slight supination. **A.** Frontal. **B.** Medial **C.** Lateral.

Radiographs revealed a medial subtalar dislocation, with evident anomalies in the talonavicular and subtalar joints (Figure 2). The CT scan did not reveal associated bone injuries (Figure 3).

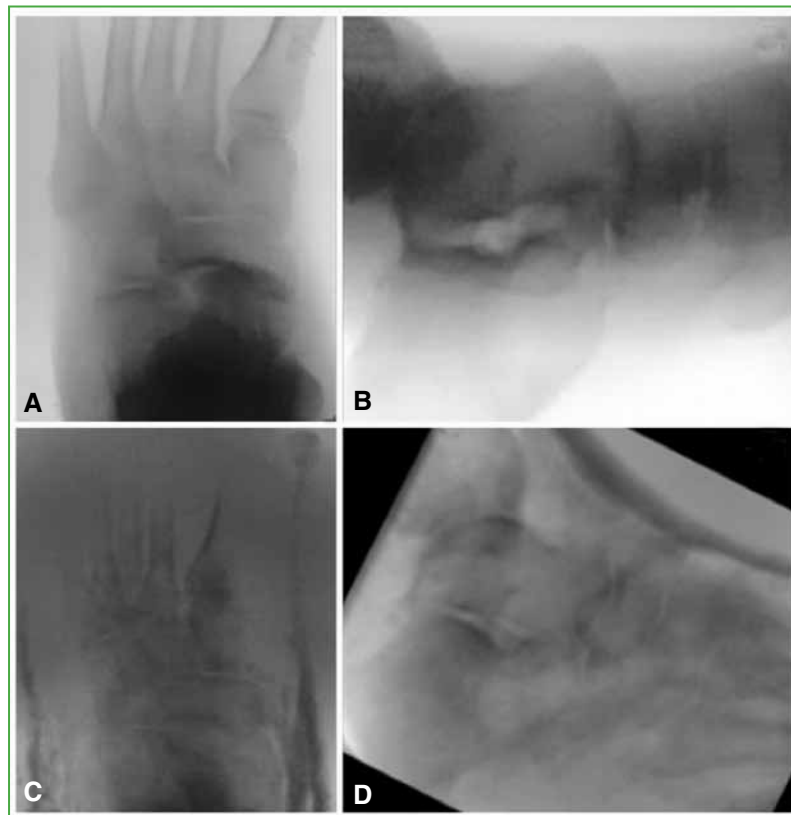

**Figure 2.** **A.** Profile radiograph displaying the incongruity in the subtalar and the talonavicular joints. **B.** Frontal radiograph revealing a medial subtalar dislocation

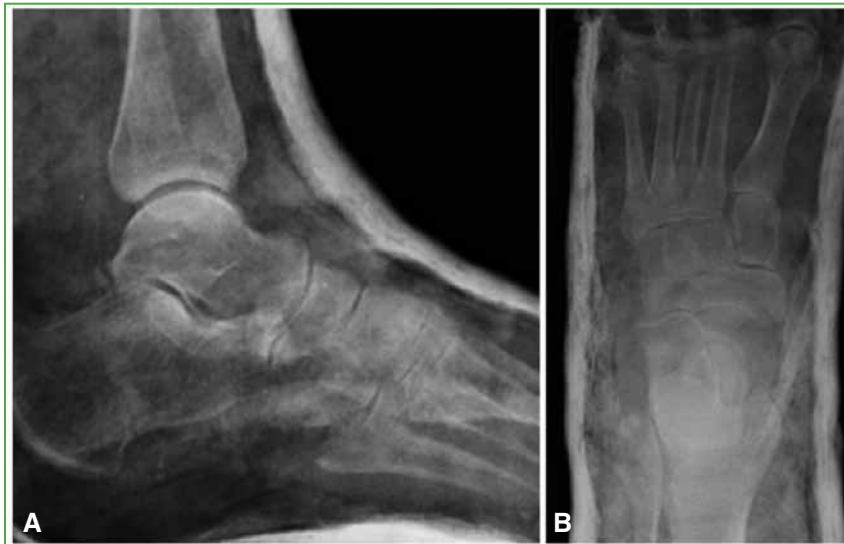

**Figure 3.** CT scan. The upper edge of the navicular is displaced to the distal position and shows impact in the anterior area of the talus.

It was decided that an urgent closed reduction was to be performed in the Operating Room under general anesthesia. In order to relax the Achilles tendon, the knee was flexed. A traction technique was applied on the axis, accentuating the deformity, in order to first reduce the impact and then, eversing the foot, a reduction was achieved. The reduction was confirmed through a radioscopy (Figure 4), a short leg plaster cast was applied, and post-operative radiographs were taken. (Figure 5)



**Figure 4.** Intraoperative radioscopy. **A and B.** Previous to the reduction. **C and D.** After the reduction.

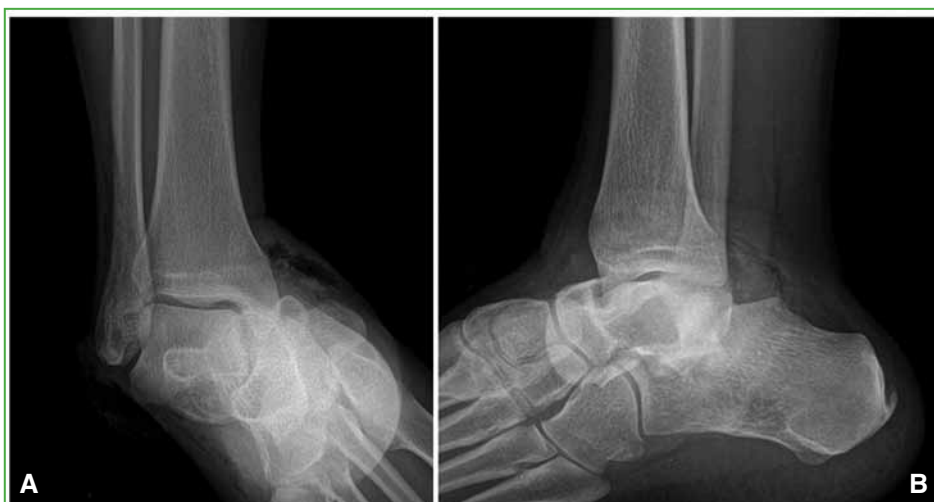

**Figure 5.** Postoperative radiographs. **A.** Profile. **B.** Front.

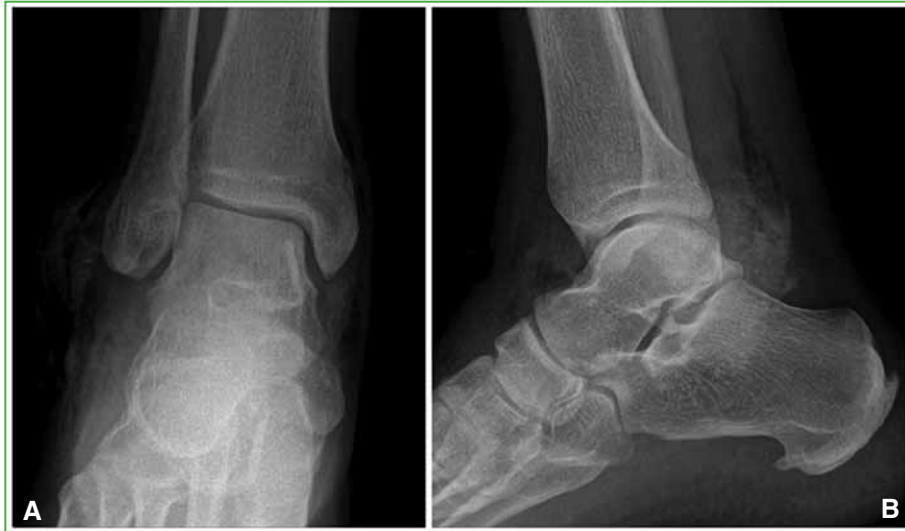She was instructed to keep the injury immobilized by the cast for four weeks. Subsequently, the plaster cast was removed and replaced by a cast brace. She was then allowed partial weight bearing starting at week 6. The patient maintained the rehabilitation protocol and she was allowed full weight bearing without restrictions after the third month. 12 months later, a long-term control showed that the patient had no symptoms and was observed to have adequate stability of the hindfoot. The visual analog scale (VAS) score was 0/10, she regained full range of motion in comparison to the opposite foot, and the AOFAS score was of 100 out of 100.

## CLINICAL CASE 2

A 43-year-old man with a right ankle injury, suffered after a fall from a height of 1 meter. He attended our ER the same day of the injury, indicating pain, functional impairment and deformity in said ankle. Radiographs showed a pure medial subtalar dislocation (**Figure 6**), which prompted an urgent reduction procedure under anesthesia (**Figure 7**).



**Figure 6.** Front (**A**) and profile (**B**) ankle radiographs. Medial subtalar dislocation.

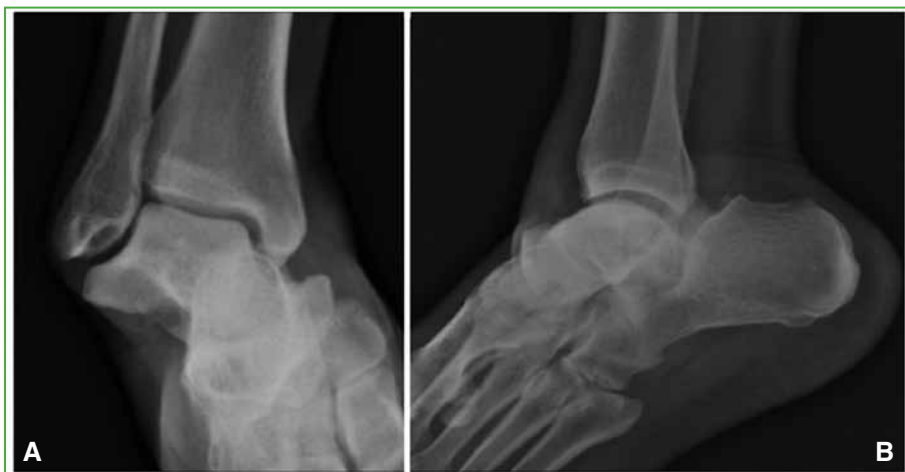

**Figure 7.** Post-reduction radiographs. **A.** Front. **B.** Profile.

He was immobilized with an short leg plaster cast. The immobilization was maintained during the course of 5 weeks, then removed and replaced by a cast brace for two more weeks. By week 6, he was allowed partial weight bearing and progressed to full weight bearing by the third month. In the 12-month follow-up, the VAS score was 2/10, with stable ankle and hindfoot, and the range of motion was fully recovered in contrast to the opposite foot. He indicated feeling slight soreness during sporting activities, and the AOFAS score was 76 out of 100. It is worth mentioning that the patient presented plantar fasciitis during evolution, which was treated with physical therapy stretching exercises and an injection (10mg betamethasone and 2% lidocaine). Symptoms then disappeared.

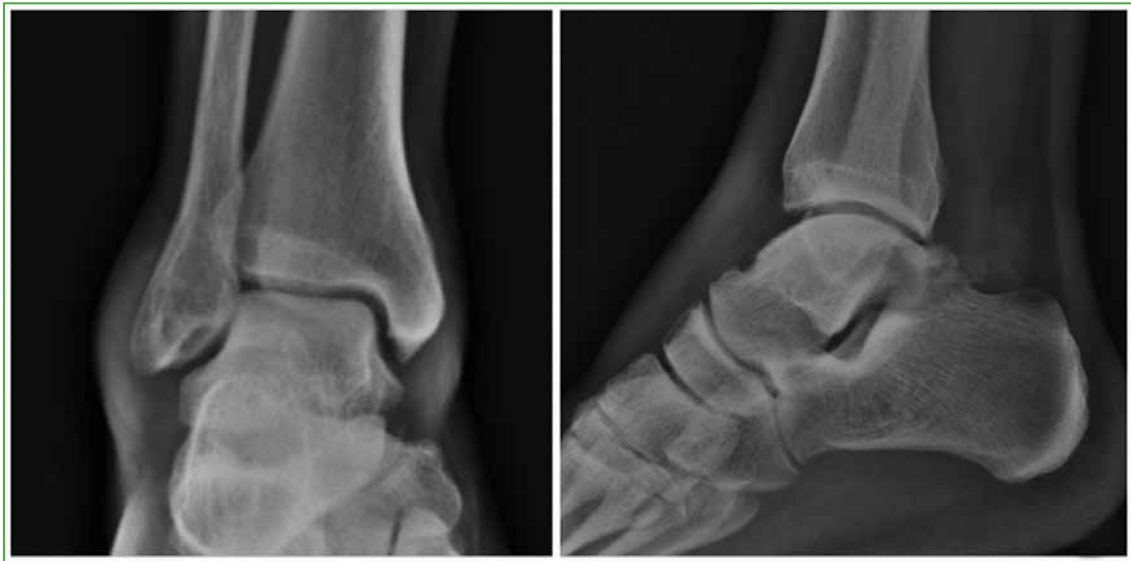### CLINICAL CASE 3

A 44-year-old man suffering from a sport-related ankle injury. He was brought in by ambulance to our ER, 6 hours after the event. He presented pain, deformity and functional impairment of the right ankle. Radiographs displayed articular incongruity with a medial subtalar dislocation (**Figure 8**).



**Figure 8.** Front (**A**) and profile (**B**) radiographs displaying the medial dislocation.

A closed reduction was performed in the Operating Room under anesthesia (Figure 9). He was immobilized with a cast and kept for four weeks, put in a cast brace for two more weeks and indicated to follow the rehabilitation protocol. Partial weight bearing was authorized after week 6, and full weight bearing at 3 months post injury. The patient interrupted the aftercare follow-ups and consulted again after two years, so the 12-month protocol was not maintained. In the long-term follow-up, the VAS score was of 0/10, he did not feel any soreness when performing sporting activities. In the physical examination, full range of motion compared to the other ankle was determined, and the AOFAS score was of 100 out of the 100 maximum.



**Figure 9.** Front (A) and profile (B) radiographs displaying the adequate reduction.

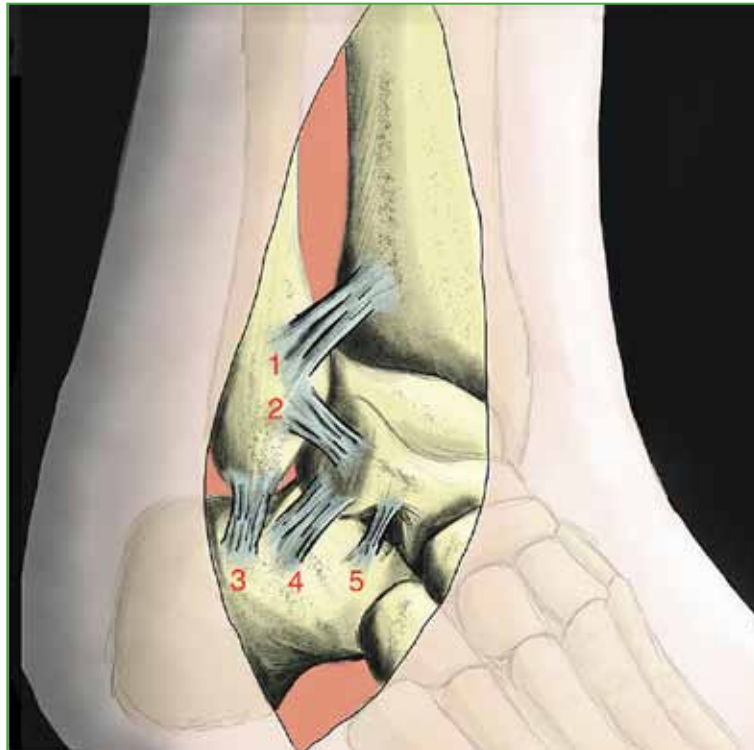
## DISCUSSION

Subtalar dislocations are atypical. They are characterized by the loss of normal anatomical links between the talus, the calcaneus and the navicular. Mailgaigne et al. classified four types of dislocation: of all four, the internal or medial variant is the most frequent, with an estimated rate range of 65-85%.<sup>3</sup> Pure dislocations remain uncommon. Some reports analyze foot and ankle injuries associated to this type of dislocations and indicate rates that oscillate between 47% and 88%.<sup>6-8</sup>

This type of dislocation is the product of forced inversions of the forefoot when the foot is in a plantar flexion. The sustentaculum tali acts as a fulcrum. If the talocalcaneal and talonavicular ligaments are injured, the talus remains in its correct position and the dislocation occurs. In a cadaveric study, Ogiuchi et al. found that both the fibulocalcaneal and the interosseous ligament as well as the talonavicular capsule had to be broken in order to recreate a medial dislocation (Figure 10).<sup>10</sup>

Inokuchi et al. classified medial dislocations in two groups: the «swift» type and the «shift» type. In the «swift» type, the calcaneus rotates to a medial, but remains below the talus, while in the «shift» type, the calcaneus deviates to a medial in relation to the talus.<sup>11</sup>

In their 25-case series, Bibbo et al. describe the most frequent early complications of subtalar dislocations: pain persistence and limitations in the range of motion.<sup>6</sup> Likewise, they used the AOFAS scoring ankle and hindfoot assessment, and found significant differences between the affected side (71 average) and its opposite (93 average). In our case series, only one patient presented differences between the affected and unaffected sides (AOFAS score of 76/100), whereas in the other two cases there was no observable contrast between both limbs.



**Figure 10.** 1. Anterior tibiofibular ligament, 2. Anterior talofibular ligament, 3. Fibulocalcaneal ligament, 4. Lateral talocalcaneal ligament, 5. Interosseous ligament.

It is a common occurrence to observe post-traumatic arthritis in the subtalar joint, as an example of all the possible complications. On the other hand, post-injury chronic pain is not quite as common.<sup>7</sup>

Previous studies determine that 10% of medial dislocations cannot be reduced through closed maneuvers and require open reductions.<sup>12</sup> The cause of difficulty or failure in the reductions may lie on the interposition of different elements, such as the extensor digitorum brevis muscle, the peroneus brevis and peroneus longus, and the capsule of the talonavicular joint. Early diagnosis, closed reductions and early immobilization are associated to a favorable prognosis.<sup>13</sup> Nonetheless, lateral dislocations and those which require an open reduction often result in improper healing.<sup>14</sup> All three patients presented in this study had suffered pure medial subtalar dislocations which were reduced urgently and within the 12-hour period after the injuries, and were promptly immobilized.

## FINAL CONSIDERATIONS

Considering that subtalar dislocations are an infrequent occurrence, they remain relevant due to the great extent of the injury. They must be regarded in association to polytrauma, traffic accidents and high-energy injuries. Diagnostic suspicion is fundamental, given that a correct diagnosis of the injury allows the application of the adequate and timely treatment, thus preventing further complications in the subtalar joint.

Presenting these three cases enables us to demonstrate the importance of diagnostic assessment and the benefits of early and accurate treatment to guarantee a favorable recovery.

Conflict of interests: Authors claim they do not have any conflict of interests.

J. E. Sánchez Saba ORCID ID: <https://orcid.org/0000-0001-5496-3513>  
 M. O. Abrego ORCID ID: <https://orcid.org/0000-0001-9783-7373>  
 F. Díaz Dilemia ORCID ID: <http://orcid.org/0000-0002-7830-2207>

F. L. De Cicco ORCID ID: <https://orcid.org/0000-0001-9844-140X>  
 F. Bilbao ORCID ID: <https://orcid.org/0000-0003-4255-3335>

## REFERENCES

1. Perugia D, Basile A, Massoni C, Gumina S, Rossi F, Ferretti A. Conservative treatment of subtalar dislocations. *Int Orthop* 2002;26:56-60. <https://doi.org/10.1007/s002640100296>
2. Tucker DJ, Burian G, Boylan JP. Lateral subtalar dislocation: review of the literature and case presentation. *J Foot Ankle Surg* 1998;37(3):239-47. [https://doi.org/10.1016/s1067-2516\(98\)80118-x](https://doi.org/10.1016/s1067-2516(98)80118-x)
3. Malgaigne JF, Burger DC. *Die Knochenbrüche und Verrenkungen*. Stuttgart, Germany: Rieger; 1856;(11):820.
4. Saltzman C, Marsh JL. Hindfoot dislocations: when are they not benign? *J Am Acad Orthop Surg* 1997;5(4):192-198. <https://doi.org/10.5435/00124635-199707000-00002>
5. Freund KG. Subtalar dislocations: a review of the literature. *J Foot Ankle Surg* 1989;28(5):429-32. PMID: 2685089
6. Bibbo C, Anderson R, Davis W. Injury characteristics and the clinical outcome of subtalar dislocations: a clinical and radiographic analysis of 25 cases. *Foot Ankle Int* 2003;24(2):158-63. <https://doi.org/10.1177/107110070302400210>
7. DeLee JC, Curtis RC. Subtalar dislocation of the foot. *J Bone Joint Surg Am* 1983;64:433-7. PMID: 7061560
8. Merchan EC. Subtalar dislocations: long-term follow-up of 39 cases. *Injury* 1992;23:97-100. [https://doi.org/10.1016/0020-1383\(92\)90041-p](https://doi.org/10.1016/0020-1383(92)90041-p)
9. Giannoulis D, Papadopoulos D, Lykissas M, Koulouvaris P, Gkiatas I, Mavrodontidis A. Subtalar dislocation without associated fractures: Case report and review of literature. *World J Orthop* 2015;6(3):374-9. <https://doi.org/10.5312/wjo.v6.i3.374>
10. Ogiuchi M, Suzuki K, Takahashi S. Experience of subtalar dislocation. *JJOTM* 1974;1172-5.
11. Inokuchi S, Hashimoto T, Usami N. Posterior subtalar dislocation. *J Trauma* 1997;42:310-13. [https://doi.org/10.1016/S0958-2592\(96\)90016-4](https://doi.org/10.1016/S0958-2592(96)90016-4)
12. Heckman JD. Fractures of the talus. En: Bucholz RW, Heckman JD (eds.). *Rockwood and Green's fractures in adults*, 5<sup>a</sup> ed. Philadelphia: Lippincott Williams and Wilkins; 2001:2091-132.
13. Merianos P, Papagiannakos K, Hatzis A, Tsafantakis E. Peritalar dislocation: a follow-up report of 21 cases. *Injury* 1988;19(6):439-42. [https://doi.org/10.1016/0020-1383\(88\)90143-x](https://doi.org/10.1016/0020-1383(88)90143-x)
14. Garofalo R, Moretti B, Ortolano V, Cariola P, Solarino G, Wettstein M, et al. Peritalar dislocations: a retrospective study of 18 cases. *J Foot Surg* 2004;43(3):166-72. <https://doi.org/10.1053/j.jfas.2004.03.008>