

Necrotizing fasciitis: Complication of osteosynthesis in medial hip fracture.

Case presentation

Marcos Latorre, Fernando Holc, Noelia B. Montenegro, José I. Oñativia

Orthopedics and Traumatology Department, Hospital Italiano de Buenos Aires, Ciudad Autónoma de Buenos Aires, Argentina

ABSTRACT

Introduction: Necrotizing fasciitis is an infrequent pathology with a high morbidity and mortality. The report of this entity in relation to hip osteosynthesis with cannulated screws is unusual. The aim of this study is to present a case of necrotizing fasciitis as a complication of hip surgery. A case about a patient with multiple comorbidities treated for a femoral neck fracture with osteosynthesis with cannulated screws is described. The patient was admitted to the emergency department of our hospital suffering from septic shock. He required emergency surgical treatment with a wide fasciotomy and a surgical toilet plus extensive debridement of necrotic tissue. The case report emphasizes the importance of recognizing the main manifestations of this disease. The diagnosis is fundamentally clinical and requires high suspicion to establish treatment early. **Conclusion:** Despite its low frequency and reporting in relation to orthopedic surgeries, it is important to consider this entity as a possible complication of surgery. Necrotizing fasciitis is characterized by its rapid and torpid evolution. Early debridement has been shown to decrease mortality and is the best treatment along with antibiotic therapy.

Key words: Necrotizing fasciitis; complications; osteosynthesis.

Level of Evidence: IV

Fascitis necrotizante como complicación de una osteosíntesis de fractura medial de cadera. Presentación de un caso.

RESUMEN

Introducción: La fascitis necrotizante es un cuadro infrecuente que provoca una alta morbimortalidad. La comunicación de esta entidad asociada a una osteosíntesis de cadera con tornillos canulados es inusual. Se describe el caso de un paciente con múltiples comorbilidades tratado por una fractura medial de cadera mediante una osteosíntesis con tornillos canulados. El paciente ingresó con un cuadro de shock séptico. Requirió cirugía de urgencia con fasciotomía amplia y limpieza quirúrgica más desbridamiento extenso de tejido necrótico. Esta presentación hace hincapié en la importancia de reconocer las principales manifestaciones de esta enfermedad. El diagnóstico es fundamentalmente clínico y requiere de una alta sospecha para instaurar un tratamiento precoz. **Conclusiones:** A pesar de su baja frecuencia y los escasos reportes relacionados con cirugías ortopédicas, es importante tener en cuenta esta entidad como una posible complicación de la cirugía.

Palabras clave: Fascitis necrotizante; complicaciones; osteosíntesis.

Nivel de Evidencia: IV

INTRODUCTION

Necrotizing fasciitis is a rare entity with a high morbidity and mortality when early diagnosis fails. It is a bacterial infection which mainly affects fascia and subcutaneous cell tissue, and can extend to muscles and skin. Early diagnosis, intravenous antibiotic administration and rapid surgical intervention are crucial to successful treatment.

Received on April 3rd, 2020. Accepted after evaluation on June 29th, 2020 • M. LATORRE, MD • marcos.latorre@hospitalitaliano.org.ar

 <https://orcid.org/0000-0002-2172-2542>

How to cite this paper: Fascitis necrotizante como complicación de una osteosíntesis de fractura medial de cadera. Presentación de un caso. *Rev Asoc Argent Ortop Traumatol* 2021;86(1):91-98. <https://doi.org/10.15417/issn.1852-7434.2021.86.1.1086>

The aim of this article is to present a case of necrotizing fasciitis after a femoral neck fracture treated with cannulated screws. We consider early recognition and treatment of this complication during postoperative follow-up of patients to be important in order to decrease its associated morbidity and mortality. Knowledge of its signs, risk factors and natural progression is fundamental in order to administer an effective treatment.

CLINICAL CASE

A 62-year-old patient who had undergone osteosynthesis of the right hip after a Garden 1 femoral neck fracture, 40 days earlier, in another institution (Figure 1). The patient was admitted to our emergency department suffering from septic shock. The patient was awaiting heart and kidney transplantation and presented diabetic nephropathy, hypertension, dilated cardiomyopathy and coronaropathy. 20 days post-surgery, he had cellulitis of the surgical wound. Given the poor response to oral antibiotics, he was admitted to receive intravenous treatment.

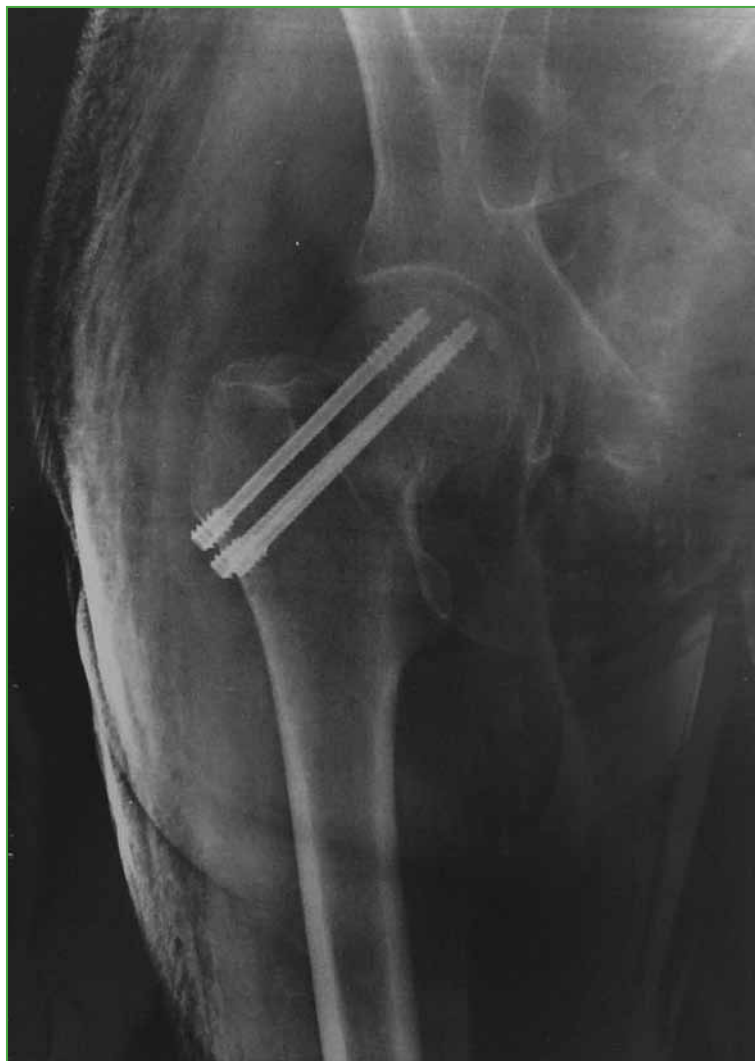

Figure 1. Immediate postoperative anteroposterior radiograph of the right hip.

Upon admittal, his general condition was unfavorable; he was somnolent, feverish and disoriented in time and space. Erythema, heat and crepitations were found on the lateral side of the right thigh, extending from the surgical wound to the medial knee region ([Figure 2](#)).

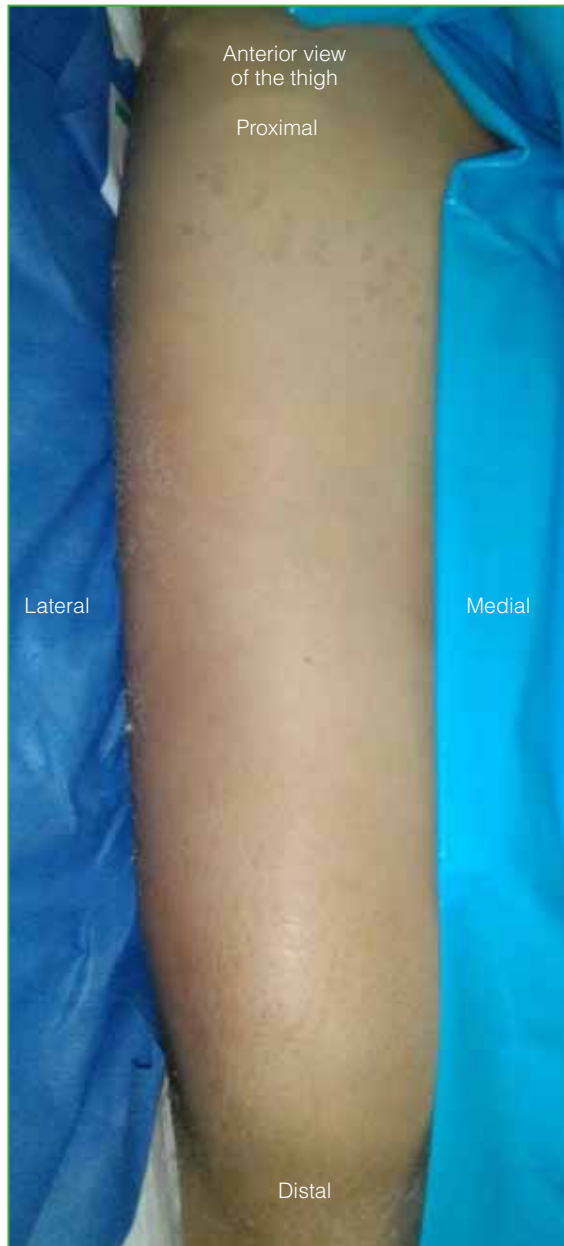

Figure 2. Clinical image of the anterior compartment of the thigh taken on admission.

Radiographs and a CT scan were performed ([Figures 3 y 4](#)), which showed radiolucent images in soft tissue across the entire thigh. Urgent surgical treatment was ordered and empirical antibiotic therapy with imipenem and vancomycin was administered.

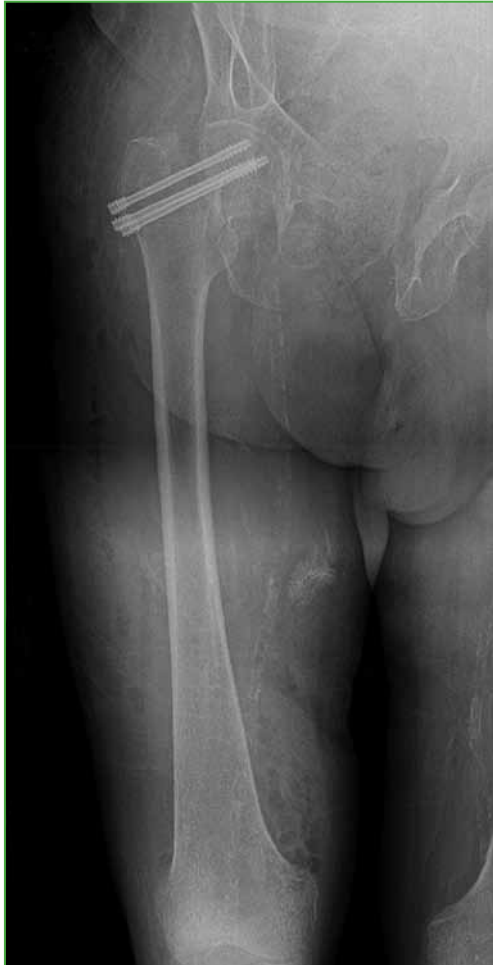

Figure 3. Anteroposterior radiograph of the right femur on admission. Note the alteration of the fracture reduction and the radiolucid images that extend over the soft tissue of the entire thigh. .

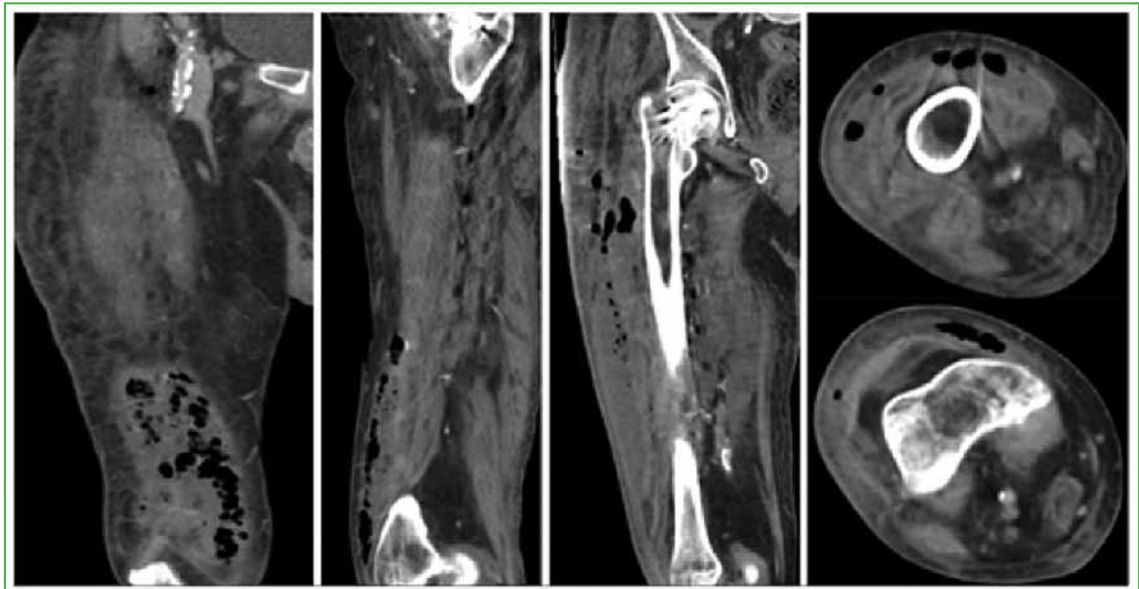


Figure 4. Computed tomography of the thigh on admission, coronal and cross section. The presence of air extending below the fascia is confirmed.

Surgery started with a lateral approach to the previous wound, which extended to the thigh and the anteromedial aspect of the knee (Figure 5A). It spontaneously drained purulent material across its entire extension and necrosis on muscle and subcutaneous tissue was found (Figure 5B). The area was cleansed with povidone iodine and abundant physiological saline solution and debridement of non-vital tissue was performed. Samples of purulent material, fascia, muscle and proximal femoral bone were collected and sent to be cultured and pathologically analyzed. Anterolateral puncture of the knee joint was performed with sterile equipment and a liquid of normal characteristics was obtained; thus arthrotomy was avoided. During the procedure, the patient became hemodynamically unstable; consequently, the procedure was concluded without removing the osteosynthesis.

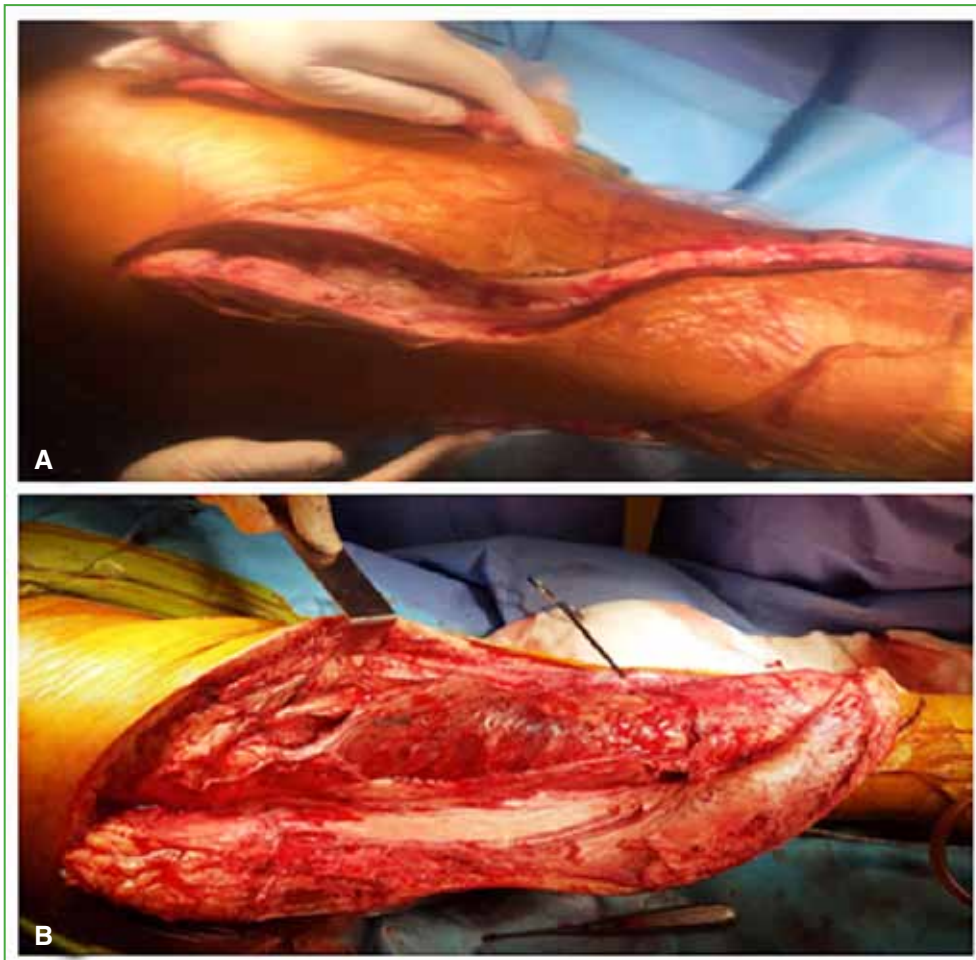


Figure 5. Clinical images of surgical treatment. **A.** Distal extension of the combined lateral and anteromedial approach on previous incision. Purulent material is observed. **B.** Appearance of vital tissue after extensive debridement.

In the immediate postoperative period, the patient required admission to the Intensive Care Unit.

Carbapenemase-Producing *Klebsiella* and *Enterococcus faecalis* were isolated in surgical cultures. The anatomopathological study revealed necrotic tissue and changes compatible with acute osteomyelitis.

Seven days after surgery, a new debridement and Girdlestone procedure were performed, and the osteosynthesis material was removed (Figure 6). The acetabular articular cartilage was resected and a cement spacer with 2 g vancomycin and meropenem was made, according to antimicrobial susceptibility. Currently, the patient's general condition is improving, he is extubated and progressively decreasing his need for inotropic support.

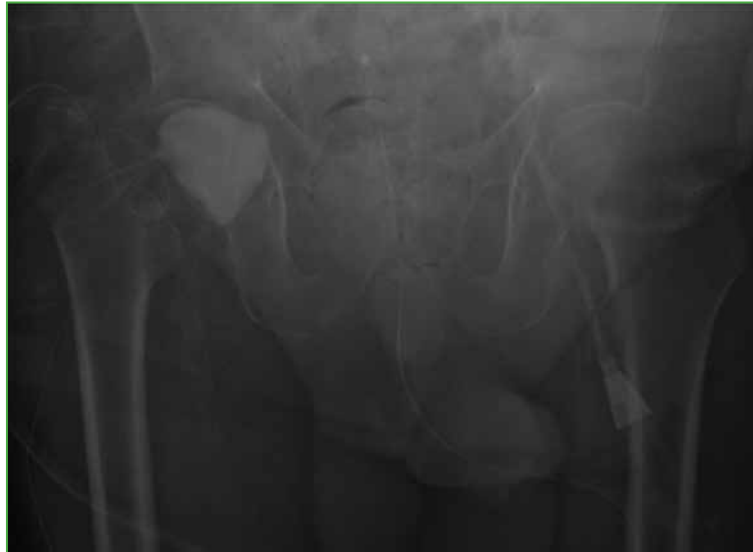

Figure 6. Anteroposterior radiograph of both hips after second surgical debridement associated with Girdlestone procedure and construction of antibiotic-impregnated cement spacer.

DISCUSSION

In the United States, necrotizing fasciitis has an incidence of 500 to 1000 cases per year, with a prevalence of 0.4 cases per 100 000 inhabitants,¹ and a mortality rate of 8.7 to 76%.² This condition encompasses various infectious entities which compromise soft tissue and are characterized by the necrosis of the various affected tissues. Since its diagnostic and therapeutical principles are similar, it is important to reduce the time between admission and surgery.²

The main risk factors for this entity are, among others, diabetes, immunosuppression, chronic kidney disease and cirrhosis.³

The diagnosis is mainly clinical and requires a high level of suspicion due to its wide variety of manifestations. Some local signs and symptoms, like erythema, high temperature, skin induration and edema, are usually mistaken for cellulitis. The most frequent symptom is disproportionate pain in the cutaneous wound (up to 100% of patients).⁴ Worsening of the condition is accompanied by necrotic progress and appearance of hemorrhagic bullae. The condition is also accompanied by general symptoms such as fever, hypotension, tachycardia and alterations in consciousness.

LRINEC Score (*Laboratory Risk Indicator for Necrotizing Fasciitis Score*), created by Wong et al.⁵ allows to discern whether an infection is necrotizing or not. It is based on six independent variables (C-reactive protein, glycemia, leukocytes, sodium, creatinine and hemoglobin) which are awarded different scores. Scores >6 have a positive predictive value of 92% and a negative predictive value of 96% (Table).⁵ Upon admission, our patient had a score of 11 (C-reactive protein 209 mg/L, leukocytes 14,000/mm³; hemoglobin 8.7 g/dL; sodium 127 mmol/L, creatinine 3.8 mg/dl; glycemia 161 mg/dL).

Table. LRINEC (*Laboratory Risk indicator for necrotizing fasciitis*) SCORE

Variable	LRINEC Score
C-reactive protein, mg/L	
<150	0
>150	4
Leukocytes, mm ³	
<15	0
15-25	1
>25	2
Hemoglobin, g/dL	
>13,5	0
11-13,5	1
<11	2
Sodium, mmol/L	
≥135	0
<135	2
Serum creatinine, mg/dL	
≤1,6	0
>1,6	2
Glycemia, mg/dL	
≤180	0
>180	1

LRINEC = *Laboratory Risk Indicator for Necrotizing Fasciitis Score*.

A score > 6 has a positive predictive value of 92% for the diagnosis of necrotizing fasciitis.

Cases of necrotizing fasciitis associated with osteosynthesis have been published. Cai et al.⁶ presented a case by *Streptococcus pyogenes* which started two days after the removal of osteosynthesis of distal radius fracture. Shang et al.⁷ described a case by methicillin-susceptible *S. aureus*, which also appeared on the second day after an osteosynthesis of tibial fracture. Both patients were treated with multiple surgical toilets, debridements and intravenous antibiotics.⁸ Since we have not found cases associated with reduction and osteosynthesis with cannulated screws in hip fractures, we consider the presentation of this case to be relevant.

CONCLUSIONS

Necrotizing fasciitis is an infrequent condition with low association to orthopedic surgery. However, it is important to consider it due to its high morbidity and mortality. Clinical evolution is the most important factor to define a case of necrotizing fasciitis. It has been shown that early debridement reduces mortality and it is the cornerstone of treatment, together with broad spectrum antibiotics.

Conflict of interests: The authors claim they do not have any conflict of interests.

F. Holc ORCID ID: <https://orcid.org/0000-0002-1224-3312>

N. B. Montenegro ORCID ID: <https://orcid.org/0000-0002-5483-9640>

J. I. Onativia ORCID ID: <http://orcid.org/0000-0001-8534-5101>

REFERENCES

1. Misiakos EP, Bagias G, Patapis P, Sotiropoulos D, Kanavidis P, Machairas A. Current concepts in the management of necrotizing fasciitis. *Front Surg* 2014;1:36. <https://doi.org/10.3389/fsurg.2014.00036>
2. Anaya DA, Dellinger EP. Necrotizing soft-tissue infection: diagnosis and management. *Clin Infect Dis* 2007;44(5):705-10. <https://doi.org/10.1086/511638>
3. Yeung YK, Ho ST, Yen CH, Ho PC, Tse WL, Lau YK, et al. Factors affecting mortality in Hong Kong patients with upper limb necrotising fasciitis. *Hong Kong Med J* 2011;17(2):96-104. PMID: 21471588
4. Young MH, Aronoff DM, Engleberg NC. Necrotizing fasciitis: pathogenesis and treatment. *Expert Rev Anti Infect Ther* 2005;3(2):279-94. <https://doi.org/10.1586/14787210.3.2.279>
5. Wong C-H, Khin L-W, Heng K-S, Tan K-C, Low C-O. The LRINEC (Laboratory Risk Indicator for Necrotizing Fasciitis) score: a tool for distinguishing necrotizing fasciitis from other soft tissue infections. *Crit Care Med* 2004;32(7):1535-41. <https://doi.org/10.1097/01.CCM.0000129486.35458.7D>
6. Cai Y, Gan Y, Yu C, Tang J, Sun Y. A successful treatment of necrotizing fasciitis following the surgery of distal radius plate removal: A case report and literature review. *Medicine (Baltimore)* 2018;97(15):e0305. <https://doi.org/10.1097/MD.00000000000010305>
7. Shang S, Zhang R, Hou Z. Necrotizing fasciitis-A catastrophic complication following routine tibia fracture surgery: A case report and literature review. *Medicine (Baltimore)* 2017;96(23):e6908. <https://doi.org/10.1097/MD.0000000000006908>
8. Wong C-H, Chang H-C, Pasupathy S, Khin L-W, Tan J-L, Low C-O. Necrotizing fasciitis: clinical presentation, microbiology, and determinants of mortality. *J Bone Joint Surg Am* 2003;85-A(8):1454-1460. PMID: 12925624