

Case Resolution

Ricardo Trueba

Magnetic Resonance and Computed Tomography Department, Grupo Médico Rostagno, Diagnóstico por Imágenes (Buenos Aires, Argentina)

See case presentation on page 97.

DIAGNOSIS

Köhler Disease (navicular osteochondrosis)

DISCUSSION

Köhler Disease is the ischemic necrosis of the navicular bone of unknown etiology. The prevailing hypothesis suggests mechanical compression of microtrauma on the navicular bone in foot longitudinal arch's apex, surrounded by already ossified bones, results in dorsal compression, vascular obstruction and bone necrosis. As with all conditions involving ossification centers, Köhler Disease may be promoted by the presence of nutritional deficiency, endocrine conditions (Hypothyroidism, growth hormone deficiency, etc.), and foot malformations (equinovarus foot deformity, metatarsus varus or adductus, brachymetatarsia of the first metatarsal bone).

Köhler Disease typically occurs in children from ages of 3 to 7 years, being more common in males (5:1 ratio). The condition is usually unilateral (80% of the cases). Presentation commonly includes pain over the dorsomedial midfoot, which results in an antalgic gait in children, with weight-bearing on the lateral side of the foot. Other signs of Köhler Disease on physical examination include local swelling, and foot rotation may potentially induce pain.

The patient was a 10-year old girl, which allows speculating that the disease evolved without clear symptoms. As an asymptomatic condition, healthcare providers may not suspect it and in its acute stage mistake it for a soft tissue injury until the adequate X-ray scan is requested for some other reason.

Bilateral involvement is rare (Picture 5), presenting different stages. The right navicular bone shows more fragmentation, but less sclerosis. The left navicular bone also shows fragmentation and higher density (sclerosis at the proximal fragment).

The diagnosis is radiological, using standard weight-bearing X-rays with AP, lateral and oblique views in internal rotation of both feet, which should evidence the flattening of the navicular bone. The different stages present areas of sclerosis, rarefaction, loss of the normal bony trabecular architecture and even irregular fragmentation. These findings may be mistaken with a normal ossification process. For this reason, 3 diagnostic criteria were established for Köhler Disease; a) changes are detected in a previously normal navicular; b) alterations consisting of resorption and ossification must be compatible with those of osteonecrosis; and c) clinical manifestations must be present.

If X-rays are inconclusive, bone scintigraphy or MRI scanning should be considered to confirm the diagnosis.

The right foot MRI (Pictures 6-8) shows fragmentation and swelling in the navicular superior sector. A black line may also be seen in T1 MRI sequences, which represent Osteosclerosis.

RICARDO TRUEBA, MD • ricardotrueba@gmail.com 

How to cite this paper: Trueba R. Postgraduate orthopedic instruction: imaging. Case resolution. *Rev Asoc Argent Ortop Traumatol* 2020;85(1):184-186. <http://dx.doi.org/10.15417/issn.1852-7434.2020.85.2.1076>.

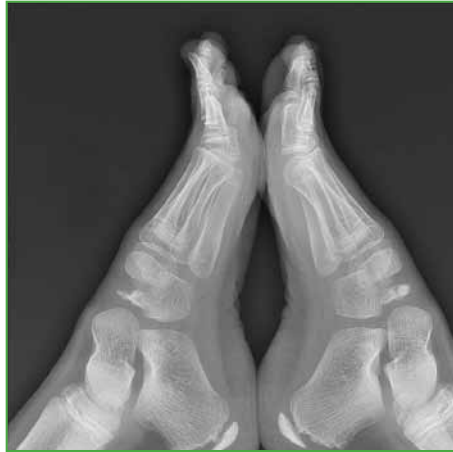

Figure 5. Both feet lateral X-rays from a patient with morphological changes in both navicular bones. The right foot image evidences more fragmentation and resorption, but less sclerosis than the left foot image. The proximal fragment of the left navicular bone shows higher density than the rest of the bone structures, due to sclerosis.

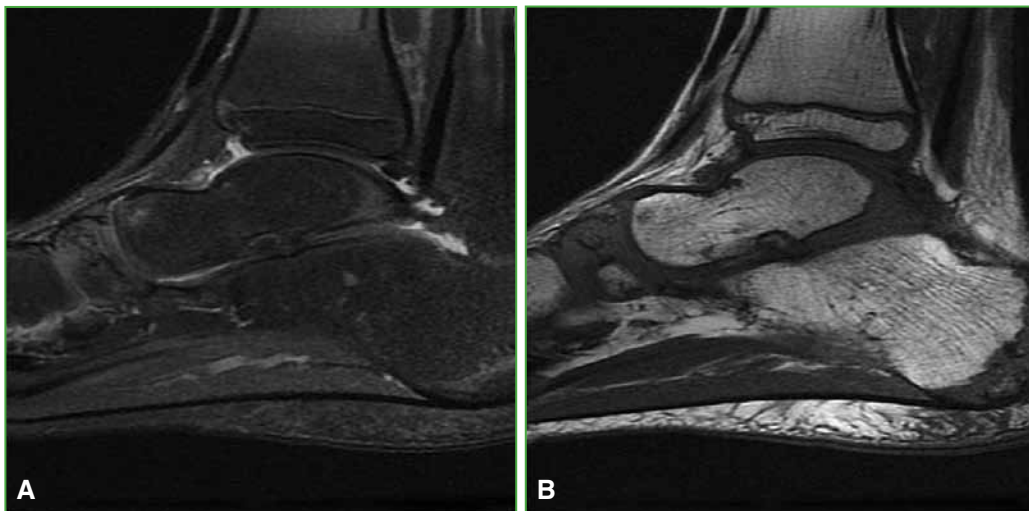


Figure 6. Sagittal MRI STIR (a) and T1-weighted (b) sequences of right navicular bone. Image reveals swelling in the right navicular superior sector with fragmentation and mild sclerosis.

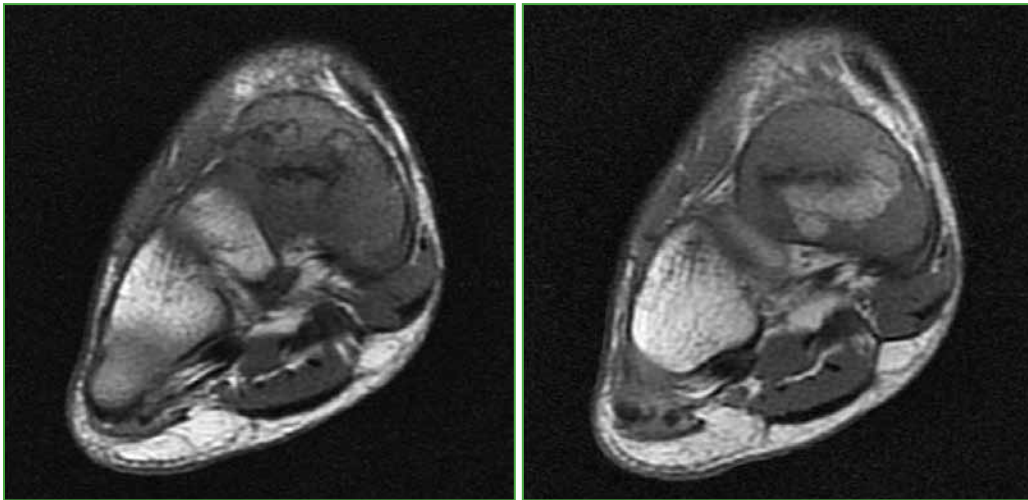


Figure 7. Coronal MRI T1-weighted sequence. Image reveals the same findings as in the right foot.

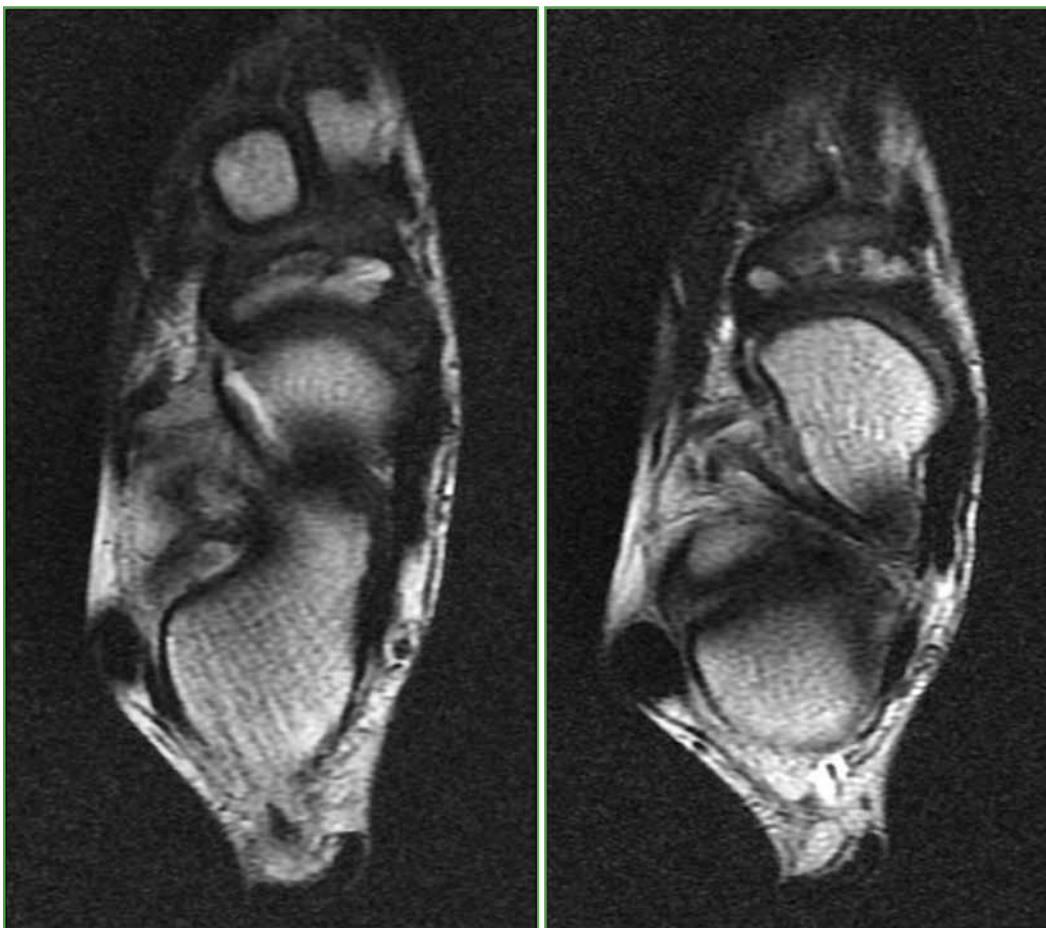


Figure 8. Axial MRI T1-weighted sequence. Image reveals the same findings as in the right foot.

Conflict of interest: Author claim he do not have any conflict of interest.