

# Non-Tuberculous Gibbus Deformity, Treated With an Implant Coated With Silver Nanoparticles. Presentation of a Case

Diego F. Jacob, Joint H. Guimbarb Perez, Luis D. E. Orosco Falcone, Juan Carlos Carabajal, Pablo N. Ortiz  
Spinal Surgery Department, Orthopedics and Traumatology Service, Sanatorio Allende, Córdoba, Argentina

## ABSTRACT

Gibbus disease is the collapse of the anterior portion of one or more vertebral bodies that results in acute angle segmental kyphosis. Generally, these types of deformities are caused by tuberculosis infections. One of the main problems associated with this deformity is spinal compression. In this case, the patient presented this condition as a consequence of a non-tuberculous infection, with angular kyphosis after osteomyelitis, treated with a double approach, using implants coated with silver nanoparticles. We obtained very satisfactory clinical and radiological outcomes. This case presents the intersection of two rare topics in current medicine; on the one hand, a type of spinal deformity that rarely occurs as a consequence of a non-tuberculous infection. On the other hand, the implant used, coated with silver nanoparticles. Although there are still controversies in the literature, this implant offers a new possibility of treatment for patients who are at increased risk of implant-related infection, and it is of interest for orthopedic surgeons, since there is sufficient evidence to support its ability to reduce the formation of biofilms.

**Key words:** Gibbus; silver nanoparticles; segmental kyphosis.

**Level of Evidence:** IV

## Deformidad de Gibbus no tuberculosa tratada con implante cubierto con nanopartículas de plata. Presentación de un caso

## RESUMEN

Se conoce como enfermedad de Gibbus al colapso de la porción anterior de uno o más cuerpos vertebrales que provoca una cifosis segmentaria de ángulo agudo. En general, este tipo de deformidades son producto de infecciones tuberculosas. Uno de los principales problemas que trae apareado esta deformidad es la compresión medular. En el caso presentado, el paciente sufrió esta enfermedad como consecuencia de una infección no tuberculosa, con cifosis angular pososteomielitis, tratado con doble vía de abordaje, utilizando implantes recubiertos con nanopartículas de plata. Los resultados clínico-radiológicos fueron muy satisfactorios. Este caso presenta la conjugación de dos temas poco frecuentes en la medicina actual; por un lado, un tipo de deformidad de la columna que, rara vez, se debe a una infección no tuberculosa y, por otro lado, el implante utilizado, recubierto con nanopartículas de plata que, pese a las controversias, ofrece una nueva posibilidad de tratamiento para pacientes con un riesgo aumentado de infección asociada a implantes, y resulta de interés que sea reconocido por los cirujanos ortopedistas, puesto que existe evidencia suficiente para afirmar su capacidad para reducir la formación de biopelículas.

**Palabras clave:** Gibbus; nanopartículas de plata; cifosis segmentaria.

**Nivel de Evidencia:** IV

## INTRODUCTION

Gibbus deformity is known as the collapse of the anterior portion of one or more vertebral bodies causing an acute angle segmental kyphosis.<sup>1</sup> The term comes from the late Latin 'gibbosus', which means hunchback.<sup>2</sup>

Received on March 15<sup>th</sup>, 2020. Accepted after evaluation on July 29<sup>th</sup>, 2020 • Dr. DIEGO F. JACOB • [djacob@hotmail.es](mailto:djacob@hotmail.es)  <https://orcid.org/0000-0001-7484-0617>

**How to cite this article:** Jacob DF, Guimbarb Perez JH, Orosco Falcone LDE, Carabajal JC, Ortiz PN. Non-Tuberculous Gibbus Deformity, Treated With an Implant Coated With Silver Nanoparticles. Presentation of a Case. *Rev Asoc Argent Ortop Traumatol* 2021;86(6):802-811. <https://doi.org/10.15417/issn.1852-7434.2021.86.5.1074>

In general, these types of deformities are the result of tuberculosis infections in the spine or are secondary to congenital anomalies.<sup>1</sup> They can also be due to some fractures, metabolic diseases, such as mucopolysaccharidosis, or congenital infections.<sup>3</sup> One of the main problems of this condition is the progression of kyphosis, since the sagittal balance worsens and, consequently, the risk of spinal cord compression is greater.<sup>1</sup>

Although there is a great deal of information about this deformity, it is very rarely a result of a nontuberculous infection; in our literature search, we found only one published case with this characteristic.<sup>4</sup> The patient we present suffered from this disease due to an infection associated with implants.

Rates of deep infections associated with implant placement in the spine range from 2.2% to 25%,<sup>5</sup> and the most common isolated microorganisms are low-virulence bacteria, such as *Staphylococcus epidermidis*, which grow on the implants, forming multilayer biofilms, also known as microfilms,<sup>6</sup> which allow bacteria to defend themselves against antibiotic treatments, as well as host immunity.<sup>7</sup>

Silver has been shown to have an effective antibacterial effect and can be applied to implants in the form of nanoparticles to obtain improved physical, chemical, and biological properties, with a tendency to inhibit infection in orthopedic implants.<sup>8</sup> For these reasons, research continues and acquires special relevance when faced with patients with special characteristics, such as altered bone metabolism, affected immune systems, active infections, or infections in remission.

We present an unusual case of post-osteomyelitis non-tuberculous angular kyphosis, treated with a double approach, using implants coated with silver nanoparticles.

## CLINICAL CASE

A 69-year-old man, with no relevant medical history, non-smoker, attended the consultation of a specialist in spinal pathology at our institution due to severe low back pain and pain in the front of both thighs, and weakness of the lower limbs that prevented comfortable standing and walking, associated with paresthesia.

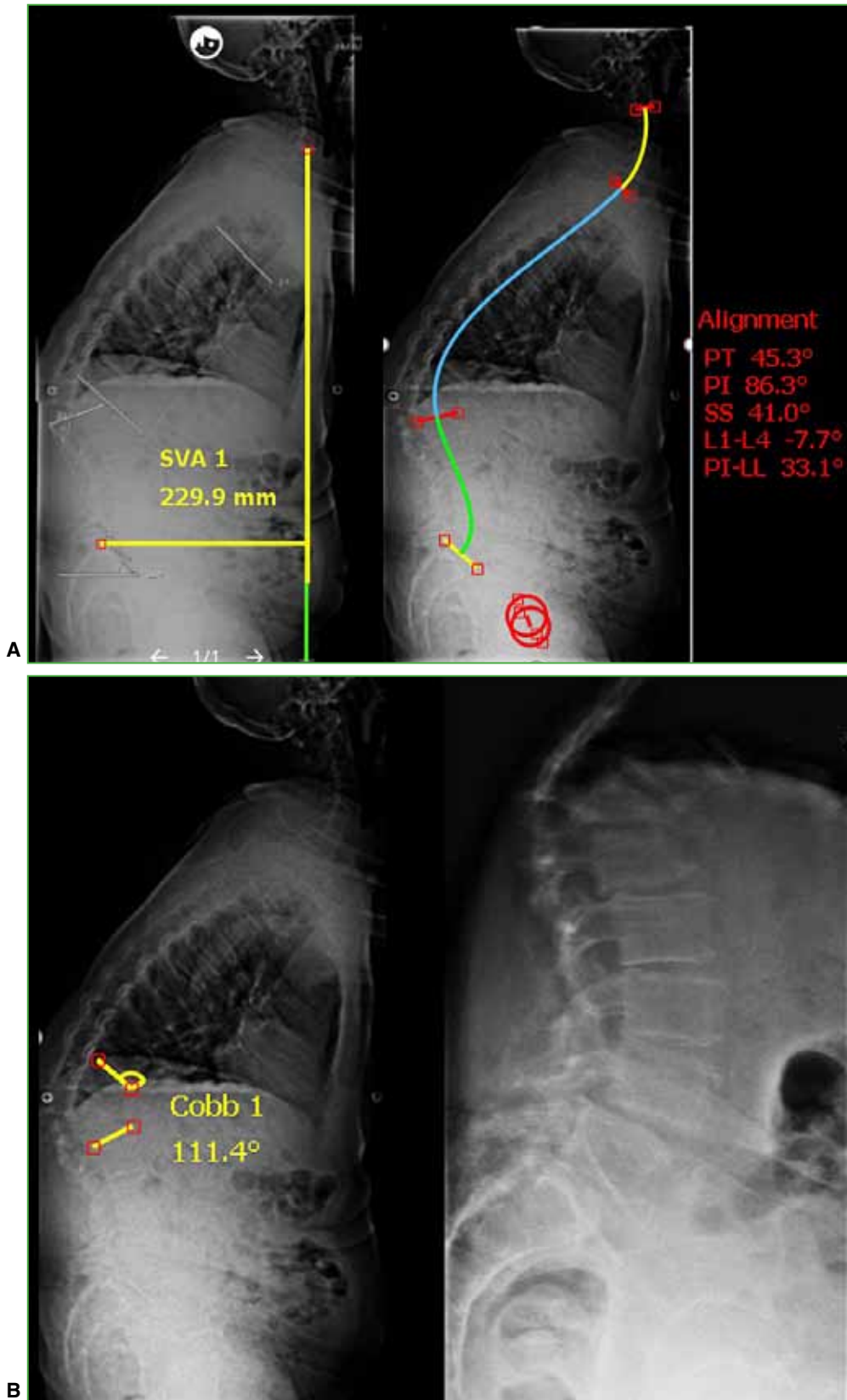
As a background, he referred to an instrumented dorsolumbar spine surgery performed two years earlier at another institution, where he had undergone a T11-S1 arthrodesis with transpedicular rods and screws, which required surgical cleaning and debridement five days later due to poor evolution of the wound. On that occasion, no germ isolation or typing was obtained. 19 months after instrumentation, the implant was removed.

At our institution, a biopsy puncture of T12 was performed under computed tomography, from which no germ was isolated. After the pertinent tests to rule out tuberculosis, he was diagnosed with T12 non-tuberculous vertebral osteomyelitis, according to the clinical presentation and imaging studies. Since the cultures were negative, the Infectology Service indicated an empirical treatment to cover gram-positive germs and gram-negative bacilli, with an adequate duration for the diagnosis of osteomyelitis, for which he was administered ciprofloxacin plus minocycline orally, for six weeks.

He was scheduled for regular check-ups until, according to clinical and biochemical parameters, the infection had cured. At the third month after the implant extraction, with the wound healed, without secretions or signs of phlogosis and due to the persistence of pain, a deformity correction surgery was planned.

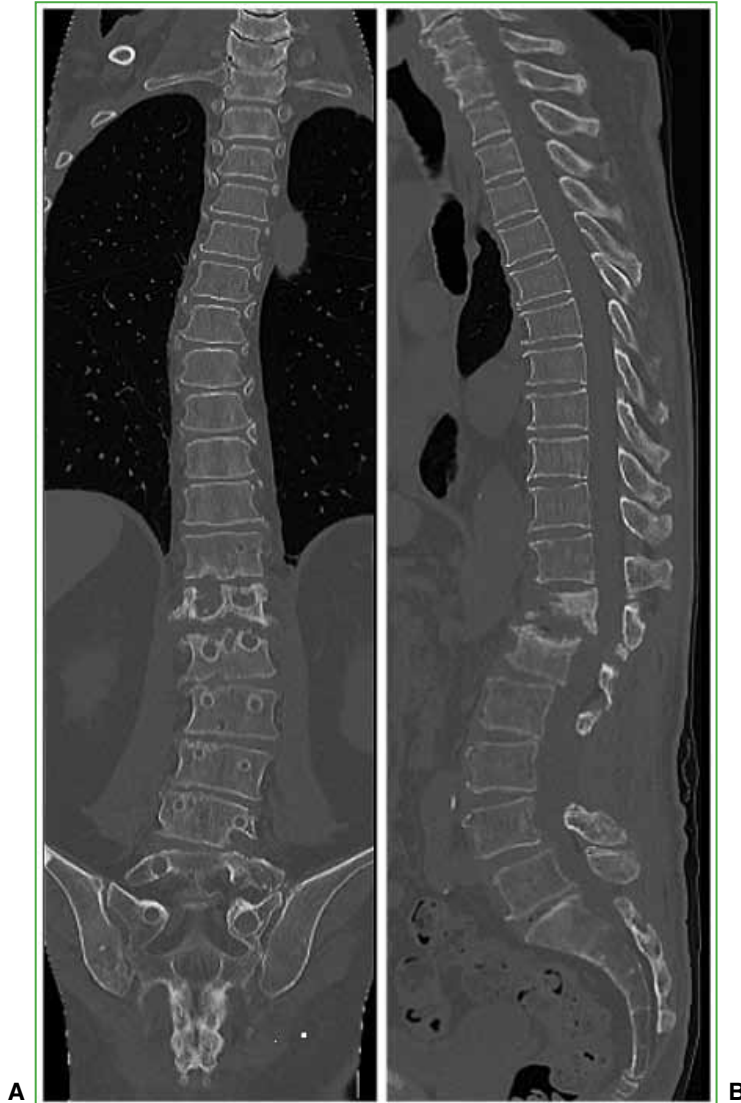
The patient was in a wheelchair, he reported low back pain associated with intense pain in the anterior aspect of both lower limbs, and the score on the visual analog scale was 9/10. In addition, he had weakness in both lower limbs, with marked muscular atrophy in both thighs and calf masses, he could walk with assistance, but he felt pain, there were no myelopathic signs, the deep tendon reflexes were preserved and the muscular strength of the lower limbs was of 3/5 according to the scale of the Medical Research Council. Upon inspection, a severe positive sagittal imbalance was observed, the Oswestry Disability Index score was 75%, which corresponds to the category of “disability”.

Imaging studies were requested. The spinogram in the standing position showed a global sagittal imbalance. With the SurgiMap® system, spinopelvic parameters were measured and the following results were obtained: very positive sagittal vertical axis (SVA) of 229 mm, with a T1-pelvis angle (TPA) of 57°, pelvic incidence (PI) 86°, pelvic tilt (PT) 45°, sacral slope (SS) 41°, thoracic kyphosis (TK) 60°, lumbar lordosis (LL) 53°, PI-LL 33°, GT 66°, and gap of 12. The patient had a Gibbus deformity at the expense of anterior wedging of T12, with T11-L1 segmental kyphosis of 111° (Figure 1).



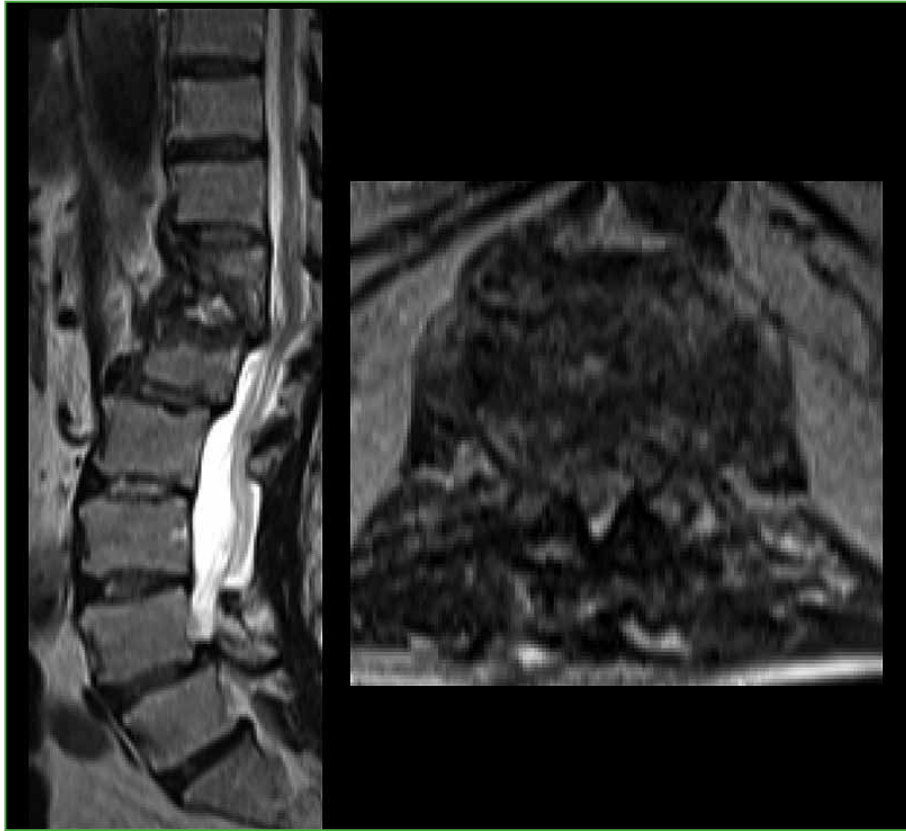
**Figure 1.** Lateral spinogram in the standing position before surgery. **A.** The value of the sagittal vertical axis is observed. **B.** Spinopelvic parameters and vertebral curves.

In the computed tomography, osteolysis of >50% of the body of T12 was observed with anterior predominance and loss of bone stock in the upper vertebral endplate of L1 plus sequelae signs of screw loosening in all the remaining levels, mainly in the sacral bone (Figure 2).



**Figure 2.** Computed tomography of the dorso lumbosacral spine. **A.** Osteolysis predominantly in the superior vertebrae of the instrumentation and the sacrum. **B.** Destruction of the T12 vertebra with large anterior wedging.

In the magnetic resonance, the narrowing of the spinal canal was visualized in T12-L1, with hyperintensity in the T2 sequence of the disc at that level, associated with the destruction of both vertebral bodies (Figure 3). In addition, a bone scan was performed that showed mild T12-L1 uptake. Biochemical parameters indicated that there was no active infection.



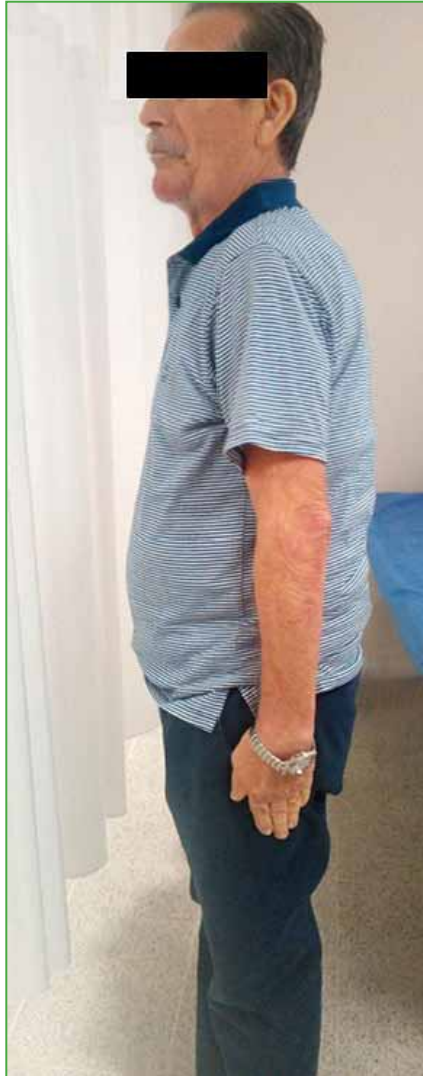**Figure 3.** MRI of the dorso lumbosacral spine showing the resulting narrowing of the medullary canal.

### Surgical technique

A first anterior surgical stage was performed by thoracotomy, with excision of the 12th rib and corpectomy of T12, and placement of a self-expanding telescoped cage with autologous rib bone graft and lateral screws to the body of T11 and L1 joined with a titanium rod, all coated with silver nanoparticles to prevent biofilm formation. Seven days later, the second subsequent surgical stage was carried out under neurophysiological monitoring, with arthrodesis of T4 to the pelvis using pedicle screws and three titanium rods with correction of the deformity and the placement of an autologous bone graft plus heterologous bank graft, plus decompression and myelomenigeo-radicular release of L4-L5.

The patient tolerated the procedure well and was discharged without pain with a four-point walker after 5 days.

Periodic evolution controls were carried out during the first month, after three months, and after six months. Currently, eight months after the intervention, the wound is healed and the patient walks unaided, without pain in the thoracolumbar region and mild pain in the lower limbs (score 2/10 on the visual analog scale). He has completed the neurorehabilitation plan for muscle strengthening and gait improvement, with an Oswestry Disability Index score of 20%, which corresponds to the category of “moderate functional limitation” (Figure 4). Both the patient and his relatives are very satisfied with the results obtained. The patient gave written informed consent for the publication of the case.

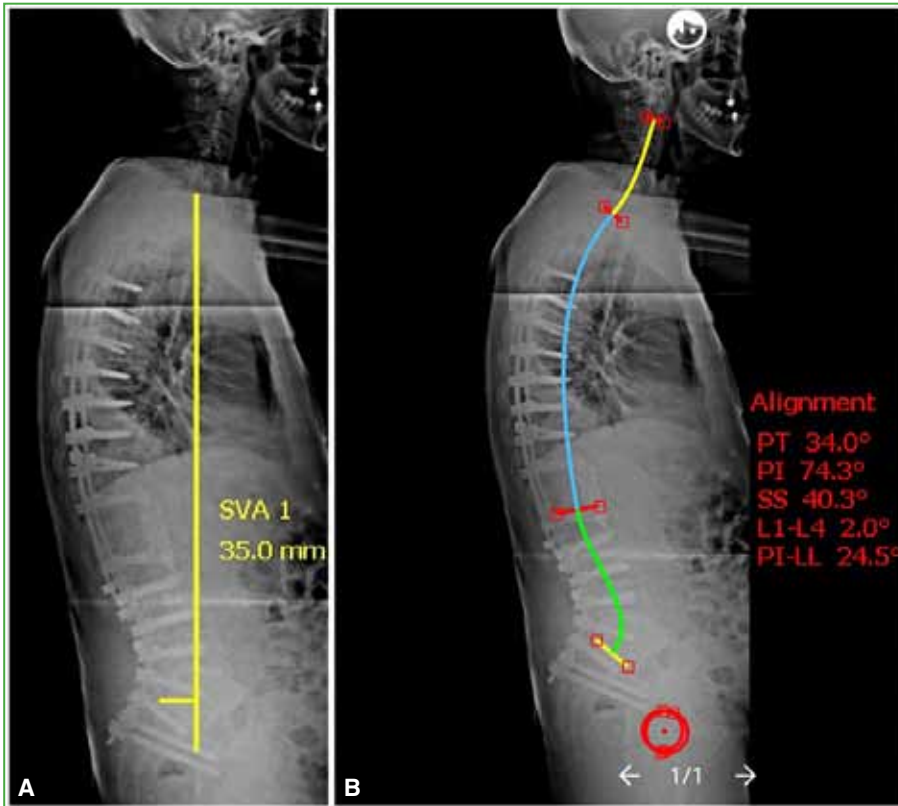


**Figure 4.** Postoperative image. Profile of the patient.

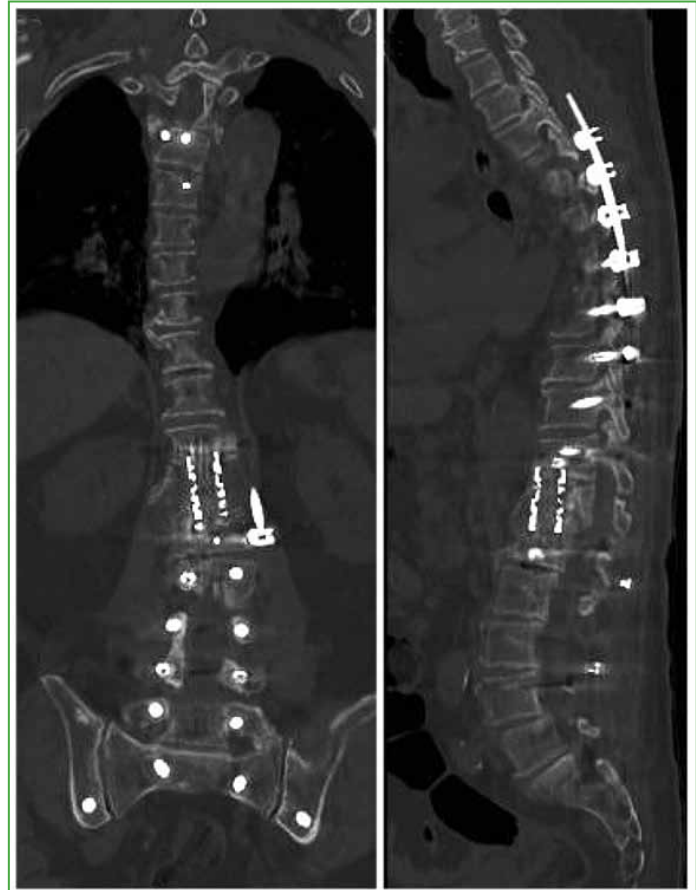In the new measurements with the SurgiMap® program, in the standing spinogram, a positive SVA of 35 mm and a segmental kyphosis T11-L1 of 11° were observed, with TPA of 27°, PI of 74°, PT of 34°, SS of 40°, TK of 37°, LL of 49°, PI-LL of 24°, GT of 29° and gap of 8, with improvement in all spinopelvic parameters (Figure 5).

On the other hand, in the computed tomography, bone consolidation, as well as the invasion of newly formed bone around the intersomatic implant, could be visualized in all planes (Figure 6).





**Figure 5.** Lateral spinogram in the standing position after surgery. **A.** Resulting sagittal vertical axis value. **B.** Spinopelvic parameters and vertebral curves obtained.



**Figure 6.** Postoperative thoracolumbosacral spine computed tomography. The bone consolidation process is observed.

## DISCUSSION

The objectives of the surgical treatment of angular kyphosis include the improvement of the neurological symptoms and the deficits due to neural compression, the restoration of normal alignment by correcting the deformity, and the stabilization of the spine with an arthrodesis.<sup>9</sup> As it can be observed in the radiological measurements described, the postoperative pelvic incidence decreased 12° with respect to the initial one, which is striking considering that this parameter has traditionally been described as “static”. However, recent studies have shown that pelvic incidence can vary with age, body mass index, after some spinal procedures,<sup>10,11</sup> and even in flexion and extension positions. The latter seems to be due to the mobility of the sacrum relative to the pelvis through the sacroiliac joint, evidenced by disproportionate changes in sacral slope versus pelvic tilt.<sup>12</sup>

To achieve therapeutic success, it is more important to obtain a solid arthrodesis than to achieve an anatomical correction of the deformity. And, based on this precept, the importance of anterior support and bone graft is clear and well documented.<sup>13</sup> Despite the advancement of surgical techniques for anterior stabilization and posterior decompression, the ideal surgical procedure remains controversial.

In those spinal instabilities where the anterior, middle and posterior columns are affected—regardless of the pathology that originated them—the successful decompression, correction of the deformity, and stabilization require anterior and posterior procedures.<sup>14</sup>

The advent of these increasingly complex surgical techniques generates, in turn, the need for implants with increasingly demanding mechanical and biological characteristics, with the ability to last a long time, mechanical resistance, little or no adverse effects on the host, relative resistance to infection, affordable costs for the health system, availability and access for the population.

These requirements have given rise to new paradigms, in which the new characteristics resulting from biomaterials do not necessarily depend on the discovery of new materials with unique properties, but rather are the result of the intelligent and combined use of materials already available.

In this context, we can affirm that the antimicrobial activity of silver is very well known; therefore, the study of this metal in the orthopedic implant industry has experienced a boom in recent times. Its bactericidal activity is based on the inactivation of key enzymes, such as succinate dehydrogenase by the attachment of thiol groups, the formation of hydroxyl radicals, and subsequent DNA damage.

In a study by van Hengel et al.,<sup>15</sup> whose objective was to develop metallic implants equipped with antimicrobial functionality to avoid associated infection, the surface of the implants was “biofunctionalized” using plasma electrolytic oxidation in the presence of silver nanoparticles. Silver nanoparticles were chosen because, when oxidized, they release silver ions that are known to be potent antimicrobial agents and have demonstrated strong bactericidal behavior against a broad spectrum of bacteria including methicillin-resistant *Staphylococcus aureus* through multiple mechanisms, such as damage to bacterial membranes and the production of reactive oxygen species.<sup>16</sup>

In this study, implants were incubated with methicillin-resistant *S. aureus* for 48 h, under conditions that induce biofilm formation. After 48 h of incubation, biofilms were formed in the implants of the control group, the bacteria increasingly stacked one on top of the other to form up to 4 or 5 layers. In contrast, in silver implants, fewer bacteria bound to the implant surface and no signs of biofilm formation were observed.

After an extensive search of the current literature, we have not found case series or reports where implants of these characteristics have been used in spinal surgery. However, in 2016, Hazer et al. published a study on rabbits that has achieved promising results regarding biofilm inhibition in spinal implants coated with silver nanoparticles;<sup>17</sup> in turn, Hegde et al. reached similar conclusions in a recent study on mice.<sup>18</sup>

Research has shown that silver nanoparticles and ionic silver have an antibacterial effect at concentrations that are not cytotoxic to eukaryotic cells.<sup>19</sup> However, some authors state that silver implants may be associated with toxicity, caused by high levels of silver ions.<sup>20</sup> In general, we can say that mammalian cells, which have a larger size, a superior structural and functional organization, and a greater capacity to produce extracellular matrix, are more tolerant to silver than bacterial cells.<sup>21</sup>



The short-term results of the applications of these silver implants did not show any adverse effect on the liver and kidney functions of the host.<sup>22</sup> However, at the cellular level, the impacts of silver ions on the viability and differentiation of bone cells have not yet been investigated in detail.

This is why, at present, there are growing concerns regarding the cytotoxic side effects of ionic silver and silver nanoparticles in mammalian cells and organ systems.<sup>23</sup>

In a study by Albers et al., silver particles were shown to cause cytotoxic effects in osteoblasts and osteoclasts.<sup>20</sup>

On the other hand, previous studies had already shown that both ionic silver and silver nanoparticles cause cytotoxic effects in different systems *in vitro* and *in vivo*.<sup>24</sup> There is no consensus on the toxicity of these particles for humans, most of the research on the toxicity of silver nanoparticles is based on *in vitro* cell experiments and relatively short-term animal experiments.

## CONCLUSIONS

This case presents the intersection of two unusual themes in current medicine; on the one hand, the presentation of a type of spinal deformity that rarely occurs as a consequence of a non-tuberculosis infection, the treatment of which is still controversial from a biomechanical point of view. We have reported a therapeutic method that, so far, achieves an excellent clinical outcome for the patient, with the restoration of standing, harmonic gait, and great improvement in pain and neurological symptoms. On the other hand, the use of an implant of the latest generation, coated with silver nanoparticles. Although it is still under study and, for some authors, its use is controversial for the reasons described above, it offers a new possibility of treatment for patients with a higher risk of implant-related infection. There is evidence supporting its ability to reduce biofilm formation, which should be taken into account by orthopedic surgeons.

Conflict of interest: The authors have no conflicts of interest to declare.

J. H. Guimard Perez ORCID ID: <https://orcid.org/0000-0002-8887-8947>  
L. D. E. Orosco Falcone ORCID ID: <https://orcid.org/0000-0003-0988-305X>

J. C. Carabajal ORCID ID: <https://orcid.org/0000-0003-2902-4420>  
P. N. Ortiz ORCID ID: <https://orcid.org/0000-0001-7461-3879>

## REFERENCES

- Ghandi M, Aycok RD, Berwald N, Hahn B. Gibbus deformity. *J Emerg Med* 2015;49(3):340-1. <https://doi.org/10.1016/j.jemermed.2015.04.004>
- Merriam-Webster. Gibbous. En: *Merriam-Webster.com dictionary*. Available at: <https://www.merriam-webster.com/dictionary/gibbous>
- Palmucci S, Attinà G, Lanza ML, Belfiore G, Cappello G, Foti PV, et al. Imaging findings of mucopolysaccharidoses: a pictorial review. *Insights Imaging* 2013;4(4):443-59. <https://doi.org/10.1007/s13244-013-0246-8>
- Seksenyan A, Esfahani DR, Hu K, Mehta AI. Gibbus deformity after non-tuberculosis osteomyelitis. *J Spine Surg* 2017;3(4):736-9. <https://doi.org/10.21037/jss.2017.12.02>
- Maciejczak A, Wolan-Nieroda A, Wałaszek M, Kołpa M, Wolak Z. Antibiotic prophylaxis in spine surgery: a comparison of single-dose and 72-hour protocols. *J Hosp Infect* 2019;103(3):303-10. <https://doi.org/10.1016/j.jhin.2019.04.017>
- Götz F. Staphylococcus and biofilms. *Mol Microbiol* 2002;43(6):1367-78. <https://doi.org/10.1046/j.1365-2958.2002.028276.x>
- Kristian SA, Birkenstock TA, Sauder U, Mack D, Götz F, Landmann R. Biofilm formation induces C3a release and protects Staphylococcus epidermidis from IgG and complement deposition and from neutrophil-dependent killing. *J Infect Dis* 2008;197(7):1028-35. <https://doi.org/10.1086/528992>

8. Qing Y, Cheng L, Li R, Liu G, Zhang Y, Tang X, et al. Potential antibacterial mechanism of silver nanoparticles and the optimization of orthopedic implants by advanced modification technologies. *Int J Nanomedicine* 2018;13:3311-27. <https://doi.org/10.2147/IJN.S165125>
9. Jung-Hee Lee, Hyun-Seok Oh, Jeong-Gyu Choi. Comparison of the posterior vertebral column resection with the expandable cage versus the nonexpandable cage in thoracolumbar angular kyphosis. *Clin Spine Surg* 2017;30(4):E398-E406. <https://doi.org/10.1097/BSD.0000000000000236>
10. Iyer S, Lenke LG, Nemani VM, Albert VM, Sides A, Metz LN, et al. Variations in sagittal alignment parameters based on age: a prospective study of asymptomatic volunteers using full-body radiographs. *Spine (Phila Pa 1976)* 2016;41(23):1826-36. <https://doi.org/10.1097/BRS.0000000000001642>
11. Noshchenko A, Hoffecker L, Cain CMJ, Patel VV, Burger EL. Spinopelvic parameters in asymptomatic subjects without spine disease and deformity: a systematic review with meta-analysis. *Clin Spine Surg* 2017;30(9):392-403. <https://doi.org/10.1097/BSD.0000000000000533>
12. Schroeder N, Noschenko A, Burger E, Patel V, Cain C, Ou-Yang D, et al. Pelvic incidence changes between flexion and extension. *Spine Deform* 2018;6(6):753-61. <https://doi.org/10.1016/j.jspd.2018.03.008>
13. Winter RB. Congenital scoliosis. *Clin Orthop Relat Res* 1973;93:75-94. Available at: [https://journals.lww.com/clinorthop/Citation/1973/06000/Congenital\\_Scoliosis.10.aspx](https://journals.lww.com/clinorthop/Citation/1973/06000/Congenital_Scoliosis.10.aspx)
14. Böhm H, Harms J, Donk R, Zielke K. Correction and stabilization of angular kyphosis. *Clin Orthop Relat Res* 1990;(258):56-61. PMID: 2394059
15. van Hengel IAJ, Riool M, Fratila-Apachitei LE, Witte-Bouma J, Farrell E, Zadpoor AA, et al. Selective laser melting porous metallic implants with immobilized silver nanoparticles kill and prevent biofilm formation by methicillin-resistant *Staphylococcus aureus*. *Biomaterials* 2017;140:1-15. <https://doi.org/10.1016/j.biomaterials.2017.02.030>
16. Rizzello L, Pompa PP. Nanosilver-based antibacterial drugs and devices: mechanisms, methodological drawbacks, and guidelines. *Chem Soc Rev* 2014;43(5):1501-18. <https://doi.org/10.1039/c3cs60218d>
17. Hazer DB, Sakar M, Dere Y, Altınkanat G, Ziyal MI, Hazer B. Antimicrobial effect of polymer-based silver nanoparticle coated pedicle screws: experimental research on biofilm inhibition in rabbits. *Spine (Phila Pa 1976)* 2016;41(6):E323-9. <https://doi.org/10.1097/BRS.0000000000001223>
18. Hegde V, Park HY, Dworsky E, Zoller SD, Xi W, Johansen DO, et al. The use of a novel antimicrobial implant coating in vivo to prevent spinal implant infection. *Spine (Phila Pa 1976)* 2020;45(6):E305-E311. <https://doi.org/10.1097/BRS.0000000000003279>
19. Amin Yavari S, Loozen L, Paganelli FL, Bakhshandeh S, Lietaert K, Groot JA, et al. Antibacterial behavior of additively manufactured porous titanium with nanotubular surfaces releasing silver ions. *ACS Appl Mater Interfaces* 2016;8(27):17080-9. <https://doi.org/10.1021/acsami.6b03152>
20. Albers CE, Hofstetter W, Siebenrock KA, Landmann R, Klenke FM. In vitro cytotoxicity of silver nanoparticles on osteoblasts and osteoclasts at antibacterial concentrations. *Nanotoxicology* 2013;7(1):30-6. <https://doi.org/10.3109/17435390.2011.626538>
21. Chernousova S, Epple M. Silver as antibacterial agent: ion, nanoparticle, and metal. *Angew Chem Int Ed Engl* 2013;52(6):1636-53. <https://doi.org/10.1002/anie.201205923>
22. Harges J, Ahrens H, Gebert C, Streitberger A, Buerger H, Erren M, et al. Lack of toxicological side-effects in silver-coated megaprotheses in humans. *Biomaterials* 2007;28(18):2869-75. <https://doi.org/10.1016/j.biomaterials.2007.02.033>
23. Ahamed M, Alsalthi MS, Siddiqui MKJ. Silver nanoparticle applications and human health. *Clin Chim Acta* 2010;411(23-24):1841-48. <https://doi.org/10.1016/j.cca.2010.08.016>
24. Asharani PV, Lianwu Y, Gong Z, Valiyaveetil S. Comparison of the toxicity of silver, gold and platinum nanoparticles in developing zebrafish embryos. *Nanotoxicology* 2011;5(1):43-54. <https://doi.org/10.3109/17435390.2010.489207>