

Superficial Circumflex Iliac Artery Perforator Flap for the Coverage of Limb Defects

Sebastián E. Valbuena,* Emanuel Pereira,* Braian Conde**

*Orthopedics and Traumatology Service, Hospital El Cruce Alta Complejidad en Red "Dr. Néstor C. Kirchner", Florencio Varela, Buenos Aires, Argentina

**Orthopedics and Traumatology Service, Hospital "Dr. Alejandro Korn", Melchor Romero, Buenos Aires, Argentina

ABSTRACT

The superficial circumflex iliac artery perforator (SCIP) flap is a thin, pliable, and versatile flap used mainly for extremities and head and neck reconstruction. Materials and methods: We presented 3 cases of SCIP flap reconstructions. Two pediatric cases for the reconstruction of traumatic sequelae of the hand and dorsal foot. One adult case for the reconstruction of a severe burn of the dorsal hand. **Conclusion:** The SCIP flap is ideal for the reconstruction of the dorsal aspect of the hand, foot, and flexion crease. Despite the anatomical variations in the origin of the superficial circumflex iliac artery, the use of microsurgical techniques and super-microsurgery allows safe harvesting of a thin flap of moderate to large dimensions, with low morbidity in the donor area.

Key words: Perforator flap; SCIP; circumflex iliac superficial artery; perforosome; inguinal.

Level of Evidence: V

Colgajo perforante de la arteria circunfleja ilíaca superficial para la cobertura de defectos en los miembros

RESUMEN

El colgajo perforante de la arteria circunfleja ilíaca superficial se utiliza para la reconstrucción de los miembros, sobre todo, en el dorso de las manos y los pies, en la zona de flexión articular y en cirugía maxilofacial, porque es un colgajo fino, flexible y versátil. Presentamos tres pacientes: dos casos pediátricos para la reconstrucción de secuelas traumáticas de la mano y el dorso del pie, y un adulto para la reconstrucción de una quemadura del dorso de la mano. **Conclusión:** El colgajo perforante de la arteria circunfleja ilíaca superficial es ideal para el dorso de la mano, el pie y los pliegues articulares. Pese a las variaciones anatómicas en el nacimiento de la arteria circunfleja ilíaca superficial, el dominio de las técnicas microquirúrgicas y de la supermicrocirugía permite tomar, con seguridad, un colgajo de dimensiones moderadas o grandes, fino, con baja morbilidad en la zona dadora.

Palabras clave: Colgajo perforante; arteria circunfleja ilíaca superficial; perforosoma; inguinal.

Nivel de Evidencia: V

INTRODUCTION

The groin flap based on the superficial circumflex iliac artery (SCIA) was described by McGregor and Jackson in 1972 for the coverage of defects in the upper limb. This flap is easy to perform, but one of its disadvantages is that the limb must be attached to the pelvic region for at least three weeks, and requires another surgical stage for its separation.¹ In 1973, Daniel and Taylor proposed its free use² and, although one of its attractive characteristics is the low morbidity in the donor area, this flap has lost popularity compared to other free flaps due to its anatomical variations.

Based on the rise of perforating flaps that allow the design of large-dimension flaps from a perforating artery, Koshima et al. described the SCIP free perforating flap for limb reconstruction,³ a very useful flap for maxillofacial and pudendal area reconstructions.

Received on December 2nd, 2019. Accepted after evaluation on August 4th, 2020 • Dr. SEBASTIÁN E. VALBUENA • valbuena.sebastian@gmail.com  <https://orcid.org/0000-0002-0209-1554>

How to cite this article: Valbuena SE, Pereira E, Conde B. Superficial Circumflex Iliac Artery Perforator Flap for the Coverage of Limb Defects. *Rev Asoc Argent Ortop Traumatol* 2021;86(6):812-820. <https://doi.org/10.15417/issn.1852-7434.2021.86.6.1035>

The possibility of taking thin flaps without the need for subsequent defatting positions the SCIP flap within the choices for limb coverage, especially on the back of the hand, foot, and joint folds.

The objective of this article is to describe the advantages of the SCIP flap and to report the resolution of three clinical cases.

CLINICAL CASE 1

A 6-year-old male who suffered an accident in his parents' bakery with the dough sheeter machine, which caused a complete degloving of the thumb and the back of the hand, and a type III amputation of the Allen and Dautel classification (distal to the interphalangeal joint). He was treated through different surgeries at a local hospital. One year after the accident, he was brought to our office. During the evaluation, we observed that the thumb was fully enclosed within the hand and that half of the distal phalanx of the thumb was missing (Figure 1).

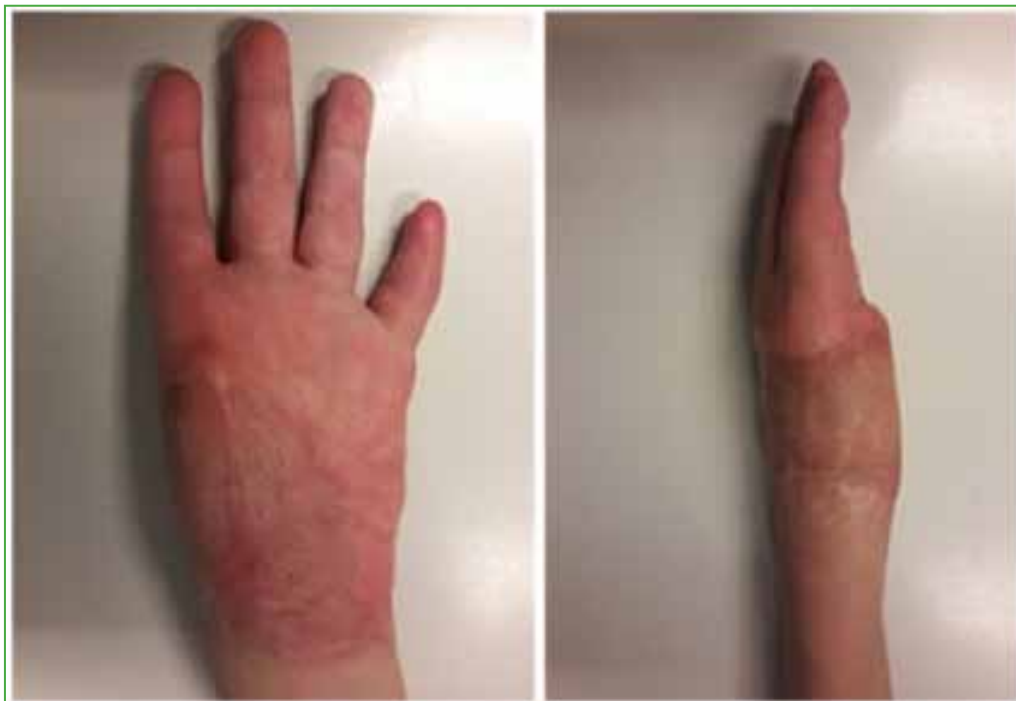

Figure 1. Sequela of injury by dough sheeter machine. Thumb avulsion with distal amputation at the level of F2, type III, with complete inclusion of the thumb in the palm.

A two-stage reconstructive surgery was planned. The first stage consisted of the reconstruction of the first commissure with the placement of the thumb in a functional position. The thumb was separated with the opening of the commissure, and the skin defect was reconstructed with a 6 x 12 cm inguinal flap based on the deep branch of the SCIA. Then we proceeded to the end-to-side anastomosis of the ulnar artery at the level of Guyon's canal and the end-to-end satellite vein anastomosis with one of the ulnar artery veins (Figure 2).

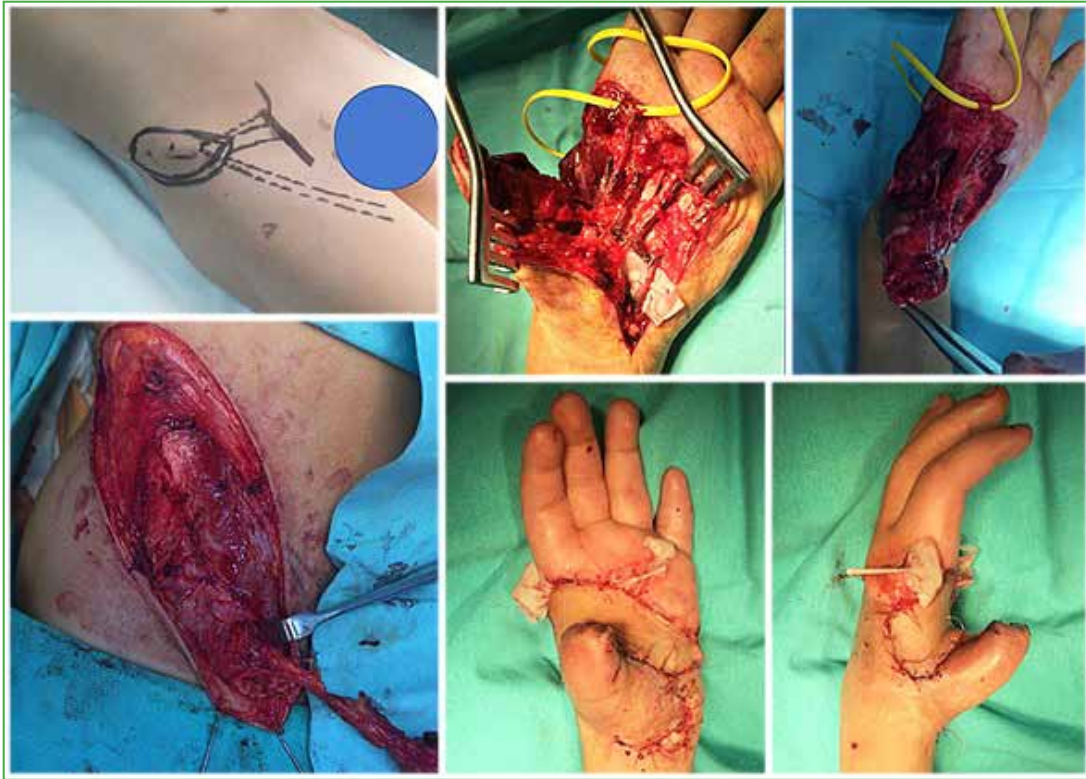


Figure 2. Thumb separation, opening of the first commissure, and carving of a free superficial circumflex iliac artery flap based on the deep branch of the superficial circumflex iliac artery.

After the rehabilitation of the range of motion of the thumb, at eight months, the second surgical stage was carried out, which consisted of reconstruction of the thumb with a transfer of the hemihallux and end-to-side anastomosis to the radial artery and two satellite veins to the veins of the back of the hand (Figure 3).

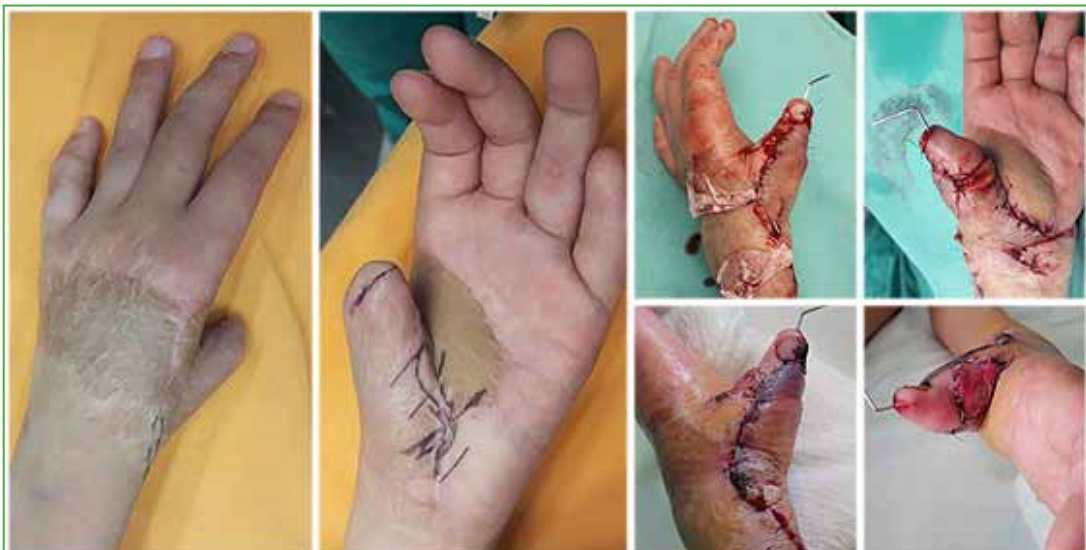

Figure 3. Second surgical stage: reconstruction of the thumb with free transfer of the hemihallux.

One year after surgery, the cosmetic appearance and the function of the thumb (Kapandji 8) are good. The only complication is a keloid scar on the back of the wrist (Figure 4).

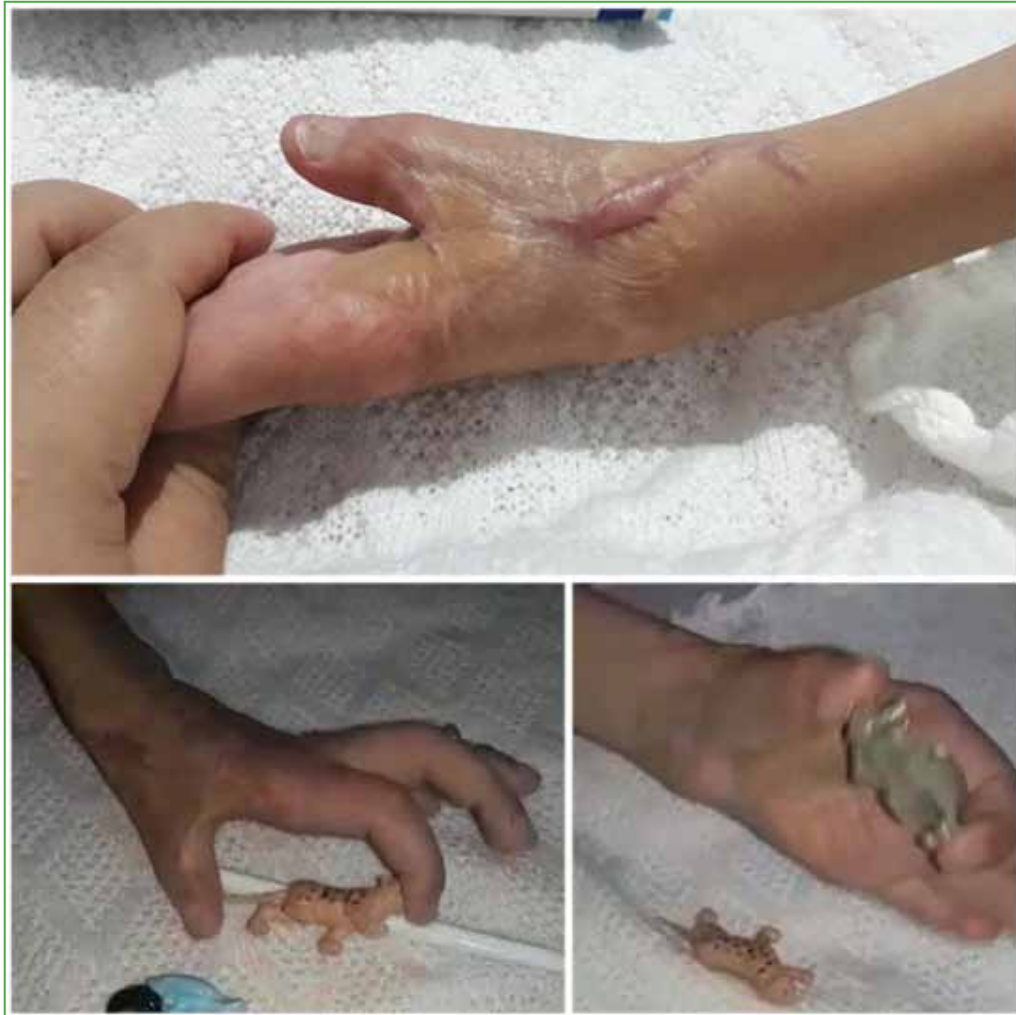

Figure 4. Excellent aesthetic and functional outcomes of the thumb. Note the keloid scar in the dorsoradial region of the wrist.

CLINICAL CASE 2

A 37-year-old epileptic woman who suffered a deep burn on the back of her hand and fingers during a seizure. At the local institution, decompression with longitudinal incisions was performed to avoid compartment syndrome (Figure 5).

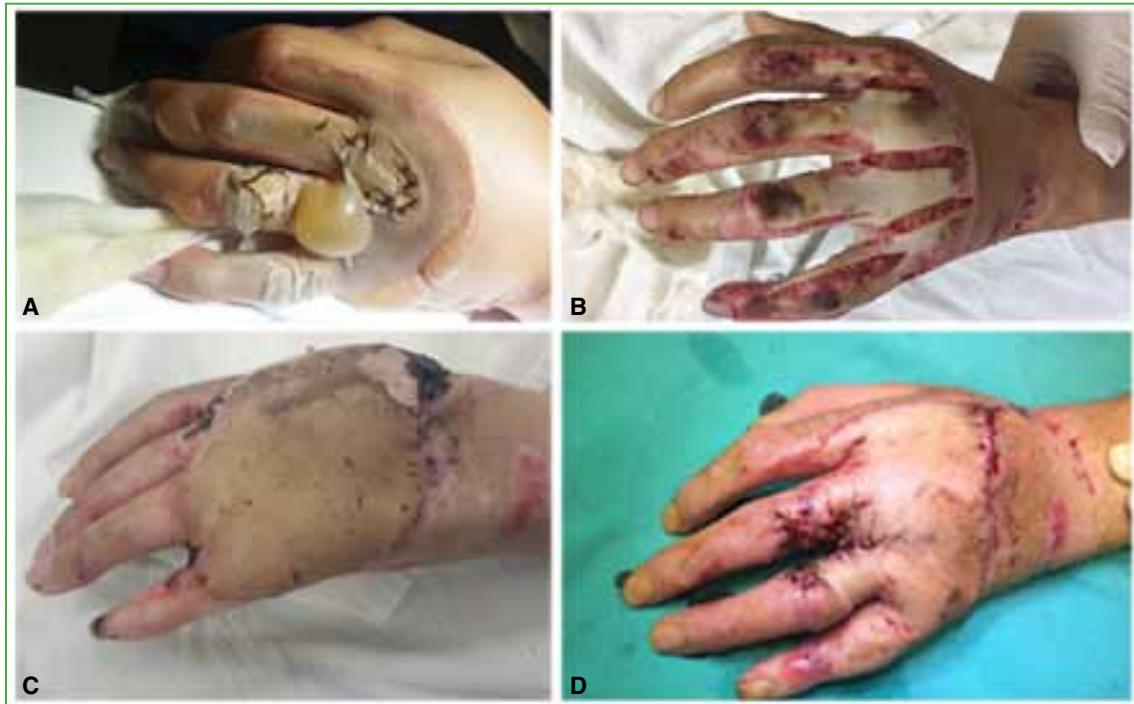

Figure 5. **A.** Deep burn of the back of the hand and fingers. **B.** Seven days after longitudinal incisions on the back of the hand and fingers. **C.** Three weeks after surgery. **D.** Five weeks after the superficial circumflex iliac artery flap, the commissures were opened.

Resection of the pathological tissue and placement of a thin SCIP flap, based on the superficial branch, was planned three weeks after the burn. Due to the need for a long pedicle to construct the radial artery anastomosis, a 14 x 7 cm distal skin flap was carved, in which the superficial perforator pedicle was embedded in a fatty flap. The anastomosis was end-to-side to the radial artery and two veins to the dorsal veins of the hand and wrist. The flap covered the entire dorsal defect and the metacarpophalangeal region of the fingers. After three weeks, the syndactyly was separated at the second and fourth commissures, and at the fifth week, the third commissure was separated. At the eighth month after the operation, the range of motion and function of the hand were complete, with an acceptable aesthetic appearance (Figure 6).

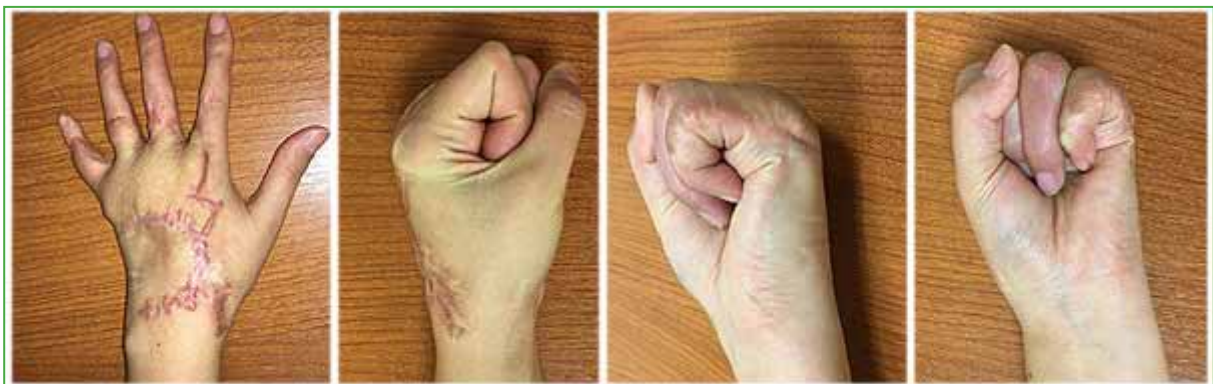

Figure 6. Eight months after surgery, the mobility of the hand is complete and the cosmetic result is excellent. A thin flap that does not require subsequent defatting.

CLINICAL CASE 3

A 5-year-old girl with a sequela of three years of evolution of a burn with boiling water on the back of her right foot, which caused skin retraction and hallux deformity in fixed extension at 90°. She was subjected to multiple Z-plasties and corrections to no avail. For 30 months, the patient had been unable to put on a shoe due to residual deformity (Figure 7).

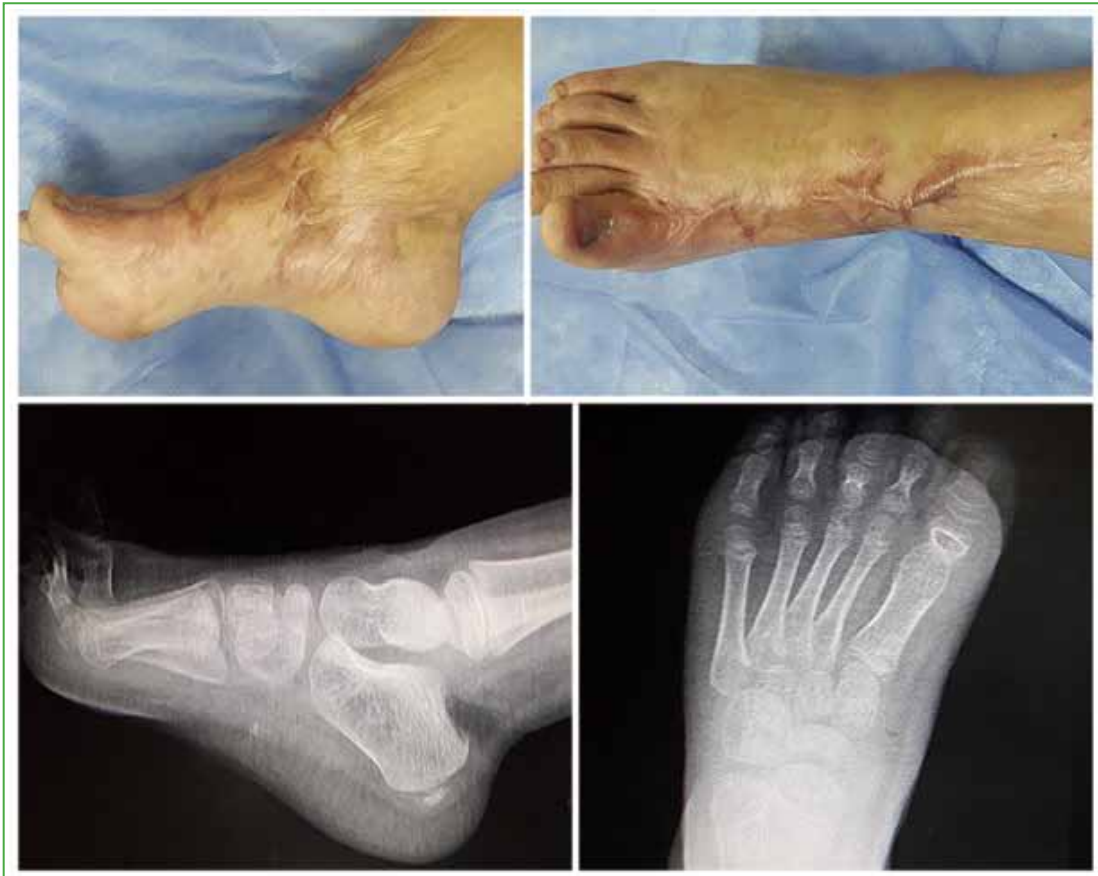

Figure 7. Burn sequela. Cutaneous retraction of the dorsum of the foot with a fixed 90° metatarsophalangeal joint extension deformity.

We proceeded to resect the scar, lengthen the hallux extensor, release the capsule and temporarily fixate the hallux in the plantigrade position. We carved a 6 x 13 cm SCIP flap based on the superficial branch. We carried out an end-to-end anastomosis to the pediatric artery and two veins, one satellite and the other superficial. Correction of the hallux was achieved and, six months after surgery, the patient could walk with footwear without problems (Figure 8).

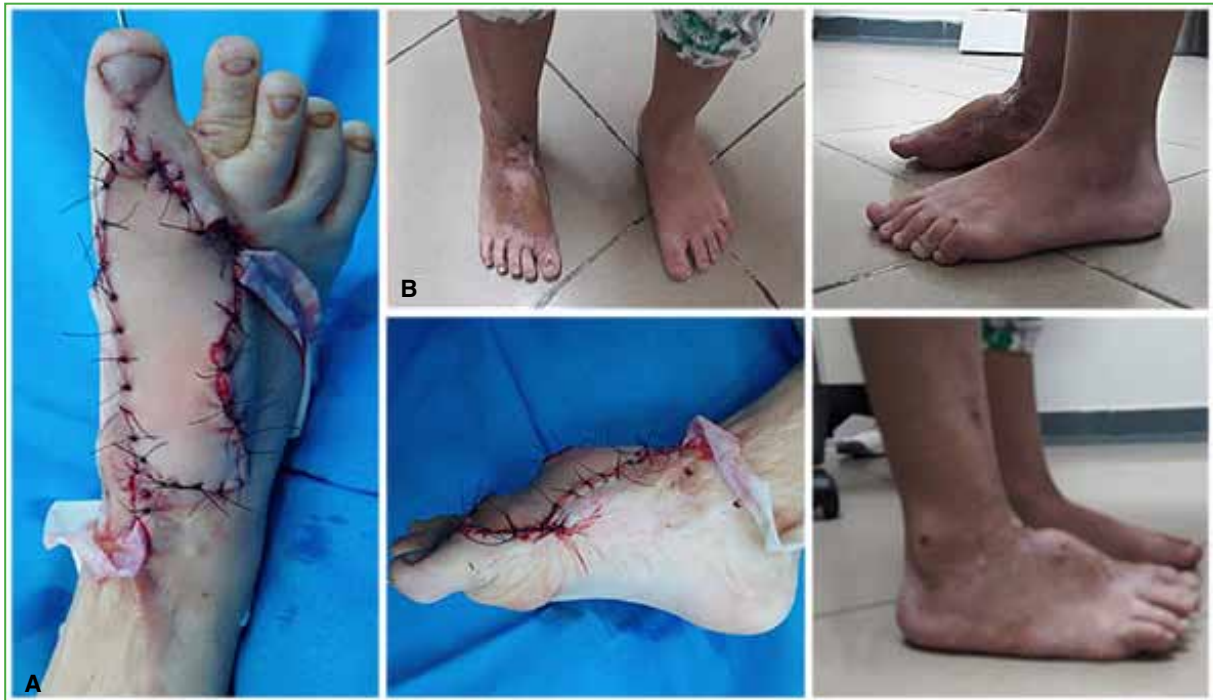

Figure 8. A. Immediate postoperative outcome. B. Outcome at four months, plantigrade support of the foot, without discomfort when wearing closed footwear.

DISCUSSION

Perforating flaps, whether helix, local, or free, have multiple advantages due to their low morbidity in the donor area and their versatility to adapt to the recipient area.⁴

Saint-Cyr et al. demonstrated that the area supplied by a perforating artery, called a perforosome, is directly and indirectly connected to other perforosomes, increasing the area of a flap from these anastomoses. The skin is irrigated by direct and indirect anastomoses of the subdermal plexus. Therefore, a large flap irrigated by a single perforator can be taken while maintaining the indirect subdermal network.⁵

In turn, due to these subdermal anastomoses, it is feasible to take thin flaps performing superficial dissections.^{6,7} These are ideal for joint folds, injuries to the hands and the dorsum of the foot, and considerably improve aesthetics and avoid subsequent defatting.⁸ The super-thin, less than 5 mm thick SCIP flap has achieved a success rate of more than 90% for moderately-sized defects.^{7,9}

The SCIA arises from the femoral artery in 83.5% of cases, from the superficial femoral artery in 8%, from the deep femoral artery in 8%, and from the deep lateral circumflex artery in 1%.¹⁰ There are also anatomical descriptions that indicate that they share a common trunk with the superficial epigastric artery in 20-30.4% of patients.^{11,12} One centimeter distal to its origin, it divides into two branches that run superior and lateral to the anterior superior iliac spine.¹⁰ The superficial medial perforating cutaneous branch penetrates the deep fascia and is directed directly to the skin. The deep branch that runs below the fascia of the sartorius muscle and irrigates it leads to a medial cutaneous perforator and a lateral perforator on the outer edge of the sartorius, then continues below the cutaneous femoral nerve.^{8,10} The deep branch of SCIA provides branches for the sartorius muscle, the cutaneous femoral nerve and the iliac crest.¹³ An advantage of this deep perforator is that it allows us to take a longer pedicle and, due to its deep anastomotic network, to obtain a chimeric flap with muscle and bone (Figure 9).

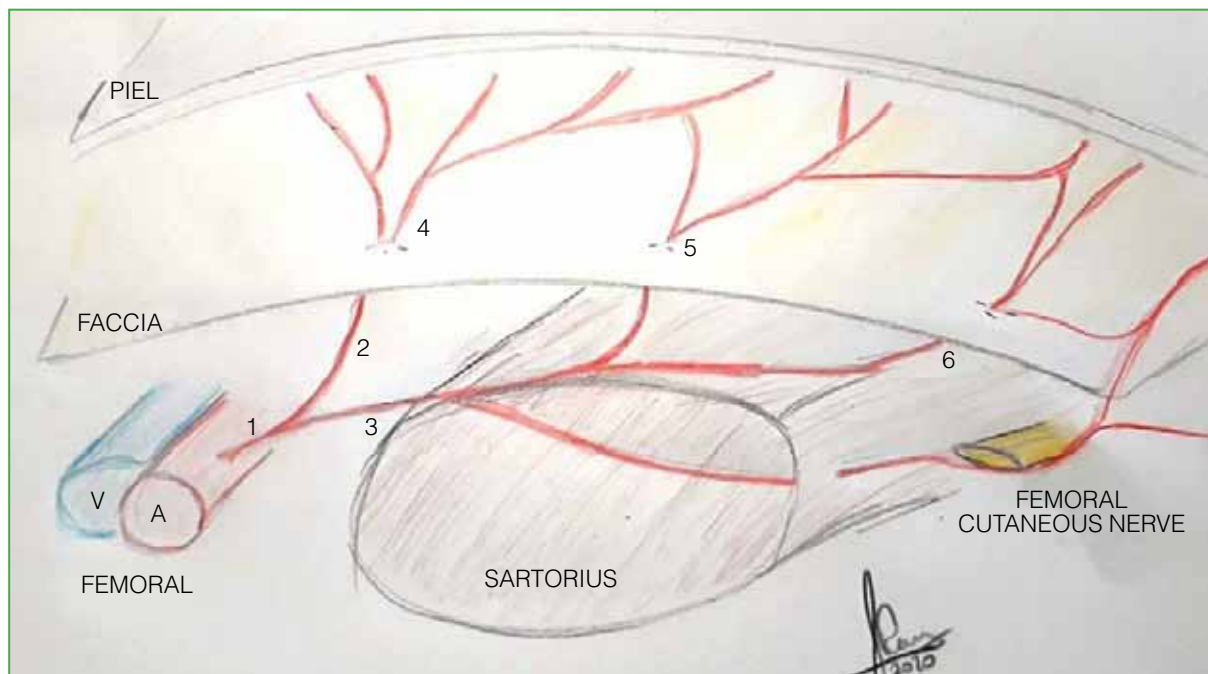


Figure 9. Irrigation scheme: 1 = superficial circumflex iliac artery, 2 = superficial branch of the superficial circumflex iliac artery, 3 = deep branch of the superficial iliac circumflex artery, 4 = medial cutaneous perforator of the superficial branch, 5 = medial cutaneous perforator of the deep branch, 6 = lateral perforator of the deep branch.

The superficial branch presents a simpler dissection and its diameter is usually greater.¹⁰ This artery is a branch of the SCIA in 96% of the cases, but its origin can be the epigastric artery, the superficial femoral artery, or the superficial pudendal artery. When this occurs and a superficial branch-based flap has been designed, it is necessary to perform a perforator-to-perforator anastomosis using supermicrosurgical techniques. Shu et al. reported that there is also 100% concordance between the surgical findings and the CT angiography in relation to the origin of this artery, and they advise carrying out this study, systematically, to predict the arterial origin. In turn, these authors describe that the superficial branch of the SCIA penetrates the deep fascia in an area of 4.2 x 2 cm, centered 4.5 cm laterally and 1.5 cm superior to the pubic tubercle. They argue that the inclusion of this area in the design of the flap allows the superficial branch of the SCIA to be included.¹⁰

A dominant perforator of the superficial or deep branch is sufficient to nourish the flap.¹⁴ Sinna et al. recommend taking the deep branch of the SCIA;¹⁵ however, Suh et al. emphasize that the superficial perforator is sufficient for the irrigation of the flap.^{10,15} Del Piñal et al. postulate that including the superficial perforator of the SCIA and the first medial cutaneous perforator of the deep branch of the SCIA is sufficient for large flaps (8 x 25 cm).⁸

Taking large flaps irrigated only by the superficial branch of the SCIA can cause a partial loss of the flap, because the superficial perforator has two forms of termination in the skin: one with axial flow in a network and the other with an anchor termination.¹⁶ This last variant is the one that could condition the partial loss in large flaps.

We consider that the superficial branch is sufficient to design moderate-sized flaps, leaving the deep branch for when larger dimensions, a long vascular pedicle, or chimeric flaps are needed.

CONCLUSIONS

The SCIP flap is ideal for the back of the hand, foot, and joint folds. Despite the anatomical variations in the origin of the SCIA, the mastery of microsurgical techniques and super microsurgery allows the safe taking of a thin, moderate to large flap with low morbidity in the donor area.

Conflict of interest: The authors have no conflicts of interest to declare.

E. Pereira ORCID ID: <https://orcid.org/0000-0001-8096-4114>

B. Conde ORCID ID: <https://orcid.org/0000-0002-4504-5128>

REFERENCES

1. McGregor IA, Jackson IT. The groin flap. *Br J Plast Surg* 1972;25(1):3-16. [https://doi.org/10.1016/s0007-1226\(72\)80003-1](https://doi.org/10.1016/s0007-1226(72)80003-1)
2. Daniel RK, Taylor GI. Distant transfer of an island flap by microvascular anastomoses: A clinical technique. *Plast Reconstr Surg* 1973;52(2):111-7. <https://doi.org/10.1097/00006534-197308000-00001>
3. Koshima I, Nanba Y, Tsutsui T, Takahashi Y, Urushibara K, Inagawa K, et al. Superficial circumflex iliac artery perforator flap for reconstruction of limb defects. *Plast Reconstr Surg* 2004;113(1):233-40. <https://doi.org/10.1097/01.PRS.0000095948.03605.20>
4. Kim JT, Kim SW. Perforator flap versus conventional flap. *J Korean Med Sci* 2015;30(5):514-22. <https://doi.org/10.3346/jkms.2015.30.5.514>
5. Saint-Cyr M, Wong C, Schaverien M, Mojallal A, Rohrich RJ. The perforasome theory: vascular anatomy and clinical implications. *Plast Reconstr Surg* 2009;124(5):1529-44. <https://doi.org/10.1097/PRS.0b013e3181b98a6c>
6. Hong JP, Choi DH, Suh H, Mukarramah DA, Tashti T, Lee K, et al. A new plane of elevation: the superficial fascial plane for perforator flap elevation. *J Reconstr Microsurg* 2014;30(7):491-6. <https://doi.org/10.1055/s-0034-1369807>
7. Jeong HH, Hong JP, Suh HS. Thin elevation: A technique for achieving thin perforator flaps. *Arch Plast Surg* 2018;45(4):304-13. <https://doi.org/10.5999/aps.2017.01529>
8. del Piñal F, García-Bernal FJ, Studer A, Ayala H, Cagigal L, Regalado J. Super-thinned iliac flap for major defects on the elbow and wrist flexion creases. *J Hand Surg Am* 2008;33(10):1899-1904. <https://doi.org/10.1016/j.jhsa.2008.09.023>
9. Kim JH, Kim KN, Yoon CS. Reconstruction of moderate-sized distal limb defects using a superthin superficial circumflex iliac artery perforator flap. *J Reconstr Microsurg* 2015;31(9):631-5. <https://doi.org/10.1055/s-0035-1558959>
10. Suh HS, Jeong HH, Choi DH, Hong JP. Study of the medial superficial perforator of the superficial circumflex iliac artery perforator flap using computed tomographic angiography and surgical anatomy in 142 patients. *Plast Reconstr Surg* 2017;139(3):738-8. <https://doi.org/10.1097/PRS.0000000000003147>
11. Nam YS, Han SH, Paik DJ. Morphometrics of arterial supply for superficial circumflex iliac artery flap in Koreans. *Korean Journal of Physical Anthropology* 2006;19(1):111. <https://doi.org/10.11637/kjpa.2006.19.1.1>
12. Del Sol M, Vasquez B. Arteria circunfleja iliaca superficial. Importancia anatómo quirúrgica. *Int J Morphol* 2013;31(2):629-32. <https://doi.org/10.4067/S0717-95022013000200046>
13. Yoshimatsu H, Steinbacher J, Meng S, Hamscha UM, Weninger WJ, Tinhofer IE, et al. Superficial circumflex iliac artery perforator flap: An anatomical study of the correlation of the superficial and the deep branches of the artery and evaluation of perfusion from the deep branch to the sartorius muscle and the iliac bone. *Plast Reconstr Surg* 2019;143(2):589-602. <https://doi.org/10.1097/PRS.0000000000005282>
14. Koshima I, Nanba Y, Nagai A, Nakatsuka M, Sato T, Kuroda S. Penile reconstruction with bilateral superficial circumflex iliac artery perforator (SCIP) flaps. *J Reconstr Microsurg* 2006;22(3):137-42. <https://doi.org/10.1055/s-2006-939957>
15. Sinna R1, Hajji H, Qassemayr Q, Perignon D, Benhaim T, Havet E. Anatomical background of the perforator flap based on the deep branch of the superficial circumflex iliac artery (SCIP Flap): a cadaveric study. *Eplasty* 2010;10:11. PMID: 20090859
16. Goh TL, Park SW, Cho JY, Choi JW, Hong JP. The search for the ideal thin skin flap: superficial circumflex iliac artery perforator flap--a review of 210 cases. *Plast Reconstr Surg* 2015;135(2):592-601. <https://doi.org/10.1097/PRS.0000000000000951>