

Severe kyphoscoliosis secondary to neurofibromatosis. Case presentation

Luis E. Nuñez Alvarado,* Edgar Morales Vásquez,** Raúl Macchiavello Falcon#

*Department of Orthopedics and Traumatology, Instituto Nacional de Salud del Niño - San Borja (Lima, Perú)

**Department of Orthopedic and Trauma Surgery, Hospital Nacional Guillermo Almenara (Lima, Perú)

***Department of Orthopedic and Trauma Surgery, Hospital Nacional María Auxiliadora (Lima, Perú)

ABSTRACT

Dystrophic scoliosis in neurofibromatosis is identifiable by being an acute-angle kyphoscoliosis involving a short segment of the spine and producing severe deformity that associated with the dystrophic changes of the spine result in real surgical challenges. We report the clinical case of a 15-year male with severe dystrophic kyphoscoliosis at the thoracolumbar area, with apex at T9, scoliosis with a Cobb angle of 107 °, and segmental kyphosis of 110.7°. The patient underwent a three-stage surgery, performed through a posterior approach, involving a vertebral column resection (VCR) and titanium mesh replacement, and achieving a kyphosis correction of 56% and a scoliosis correction of 59.8%. The patient experienced no major complications nor sequelae and had a favorable course. The VCR is a powerful and demanding surgical technique that allows for the management of the complex kyphoscoliosis deformity to achieve spinal balance; however, it is not without complications, especially neurological and pulmonary complications, which may be unavoidable. Our patient's quality of life has improved significantly.

Key words: Neurofibromatosis; scoliosis; resection; spine

Level of Evidence: IV

Cifoescoliosis severa secundaria a neurofibromatosis. Presentación de un caso

RESUMEN

La escoliosis distrófica de la neurofibromatosis se caracteriza por ser una cifoescoliosis de ángulo agudo que compromete un segmento corto de la columna vertebral y genera una gran deformidad que, sumada a los cambios distróficos de la columna, convierte a los gestos quirúrgicos para su corrección en verdaderos retos. Se presenta a un varón de 15 años con cifoescoliosis toracolumbar distrófica severa con ápice en T9, ángulo de Cobb 107° de escoliosis y 110,7° de cifosis segmentaria. Se realiza una cirugía por vía posterior en tres tiempos, mediante una resección de la columna vertebral y reemplazo con malla de titanio; se logra una corrección de la cifosis y la escoliosis del 56% y 59,8%, respectivamente. El paciente no tuvo complicaciones mayores, ni secuelas, y la evolución fue favorable. La resección de la columna vertebral es una técnica quirúrgica potente y desafiante para el manejo de la deformidad cifoescoliótica compleja necesaria para lograr el equilibrio espinal, aunque no está exenta de complicaciones, sobre todo neurológicas y pulmonares, a veces, inevitables. La calidad de vida de nuestro paciente tuvo una mejoría importante.

Palabras clave: Neurofibromatosis; escoliosis; resección; columna vertebral.

Nivel de Evidencia: IV

INTRODUCTION

Neurofibromatosis is a phakomatosis of multifactorial etiology with an autosomal-dominant genetic trait, although 50% of cases arise due to de novo mutations. Neurofibromatosis involves the proliferation of cells from the neural crest, which can occur in both the peripheral and central nervous systems.¹ There are four clinical forms of neurofibromatosis. Neurofibromatosis type 1 (NF1), also known as von Recklinghausen disease, is one of the most common, and its clinical manifestations are characterized by the presence of neurofibromas throughout the body and café-au-lait spots in the skin and other ectodermal tissues.² The incidence of NF1 is 1 in 3,000 live births.³

Received on September 19th, 2019. Accepted after evaluation on December 4th, 2019 • LUIS E. NUÑEZ ALVARADO, MD • luisenriquenunez@hotmail.com  <https://orcid.org/0000-0003-4314-3610>

How to cite this paper: Nuñez Alvarado LE, Morales Vásquez E, Macchiavello Falcon R. Severe kyphoscoliosis secondary to neurofibromatosis. Case presentation. *Rev Asoc Argent Ortop Traumatol* 2020;85(4):393-402. <https://doi.org/10.15417/issn.1852-7434.2020.85.4.1015>

The musculoskeletal manifestations in NF1 include: osteoporosis, osteomalacia, osteopenia, shortness of stature, and macrocephaly. NF1 most common orthopedic manifestations are scoliosis and congenital pseudoarthrosis (usually of the tibia) (Table).⁴

Table. Diagnostic criteria for neurofibromatosis type 1

Two or more of the following must be present:

1. Six or more café au lait spots:
 ≥15 mm in diameter in postpubertal individuals
 ≥15 mm in diameter in postpubertal individuals
2. ≥ 2 neurofibromas of any type or one plexiform neurofibroma
3. Freckling in the axillary or inguinal regions
4. Optic nerve glioma
5. ≥ 2 iris Lisch nodules
6. A distinctive bone lesion:
 Sphenoid bone dysplasia
 Dysplasia or thinning of long bone cortex
7. A first-degree relative with neurofibromatosis type 1

Taken from reference 3.

In NF1 patients, scoliosis may be nondystrophic or dystrophic. Nondystrophic scoliosis has a presentation similar to that of adolescent idiopathic scoliosis, although with earlier onset (before age 7 years) and it may progress to dystrophic scoliosis.⁵ Typical features of dystrophic scoliosis include wedging of vertebral bodies with very sharp edges, significant vertebral rotation, widening of the spinal canal and the intervertebral foramina as well as rib thinning and paravertebral tumors.³ There is more kyphosis than scoliosis, with sharply angulated deformity affecting fewer than six spinal segments, associated with vertebral wedging.⁶

An aggressive approach for the management of the dystrophic curve is recommended: curvatures of less than 20° should be routinely observed at 6-month intervals, and curvatures greater than 20-40° require spinal fusion.⁶ Treatment of severe curves may include anterior support, and, as a general rule in acute kyphotic deformities, autografting and allografting to prevent pseudarthrosis.

We report this case because there are no Peruvian reports on severe kyphoscoliosis, and perform a literature review on this condition.

CLINICAL CASE REPORT

A 15-year-old male, of mestizo ethnicity, student, with no significant family history presents with an NF1 diagnosis, thoracolumbar deformity, dorsal pain that limits his daily activities, and inability to perform physical exercise due to respiratory distress (the patient reported shortness of breath).

The physical examination revealed a large kyphosis in the left thoracolumbar region and numerous café-au-lait spots in the skin (Figure 1). The flat waist sign and Adams sign were both positive. Patient was 143cm tall, weighed 39kg, and had muscle strength 5/5. Patient presented normal bilateral sensory functions and normal and symmetric lower-limb stretch reflexes, negative bilateral Babinski signs, negative clonus, symmetric abdominal reflexes, and normal toe-heel walk.

The preoperative total score on the Scoliosis Research Society-22 questionnaire (SRS 22)⁷ was of 2.8/5 (function 3.2/5; pain 4.2/5; self-image 2.2/5; mental health 1.8/5; management satisfaction/dissatisfaction 2/5).

Coronal plane radiographic evaluation revealed a significant double-curve scoliosis deformity at thoracic level, showing dystrophic features and acute angulation; Cobb angle of the main thoracic curve was 107°, and Cobb angle of the proximal thoracic curve was 52.3°, which respectively decreased to 92.4° and 38.2° on side-bending radiographs; and coronal balance was -34.7 mm, with balanced shoulders. Sagittal plane radiographic evaluation revealed a 110.7° segmental kyphosis, a 130.3° kyphosis at T4-T12, a +71.8mm sagittal balance, a -80.4° lumbar lordosis, a 44.7° pelvic incidence, a 10.5° pelvic inclination, and a 34.2° sacral slope (Figure 2).

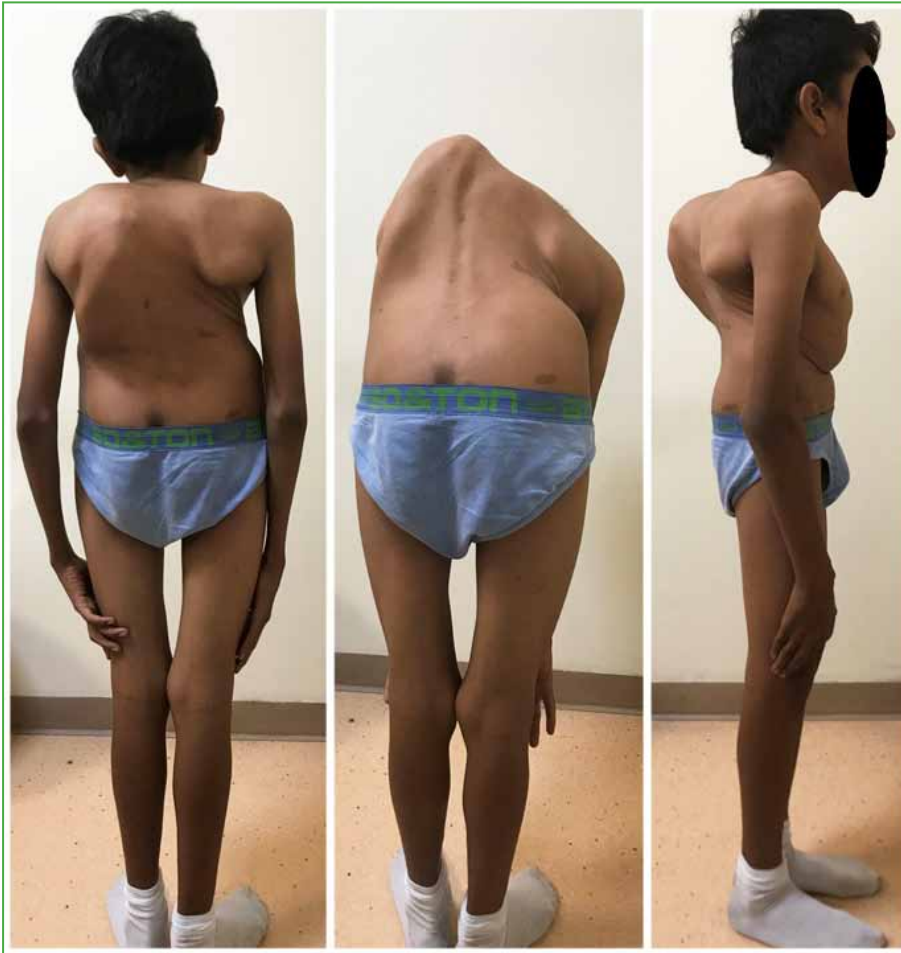

Figure 1. Photographs of the physical evaluation, frontal view, Adam's test, lateral view.

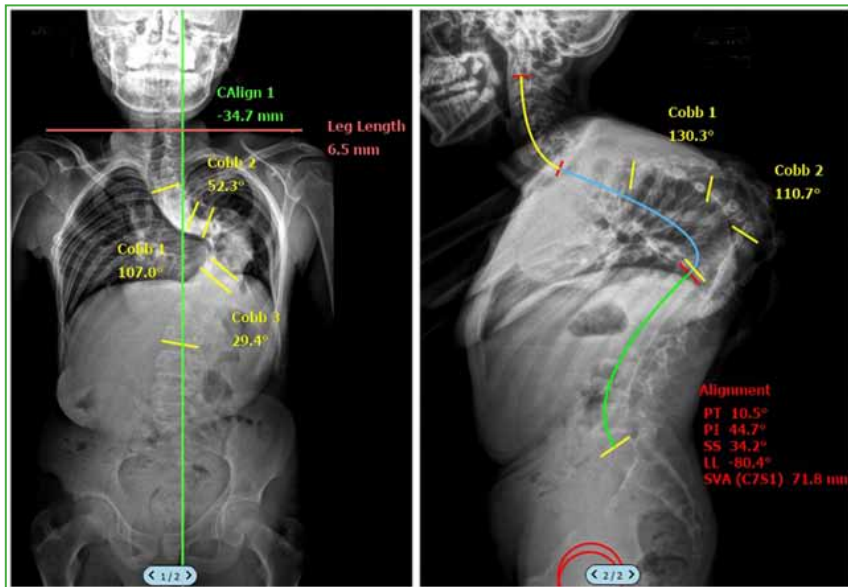


Figure 2. Anteroposterior and lateral spinal radiography: Cobb angle of 107°, -34.7mm coronal balance, 110.7° segmental kyphosis, 130.3° overall kyphosis, and 71.8mm sagittal balance.

CT imaging revealed telltale dystrophic changes of neurofibromatosis, such as the widening of the spinal canal and the intervertebral foramina, rib thinning, pedicular dysplasia, and vertebral wedging. MRI imaging revealed the typical dural ectasia but no neurofibromas. At the apex level, there was a displacement of the spinal cord to the concavity (Figure 3).

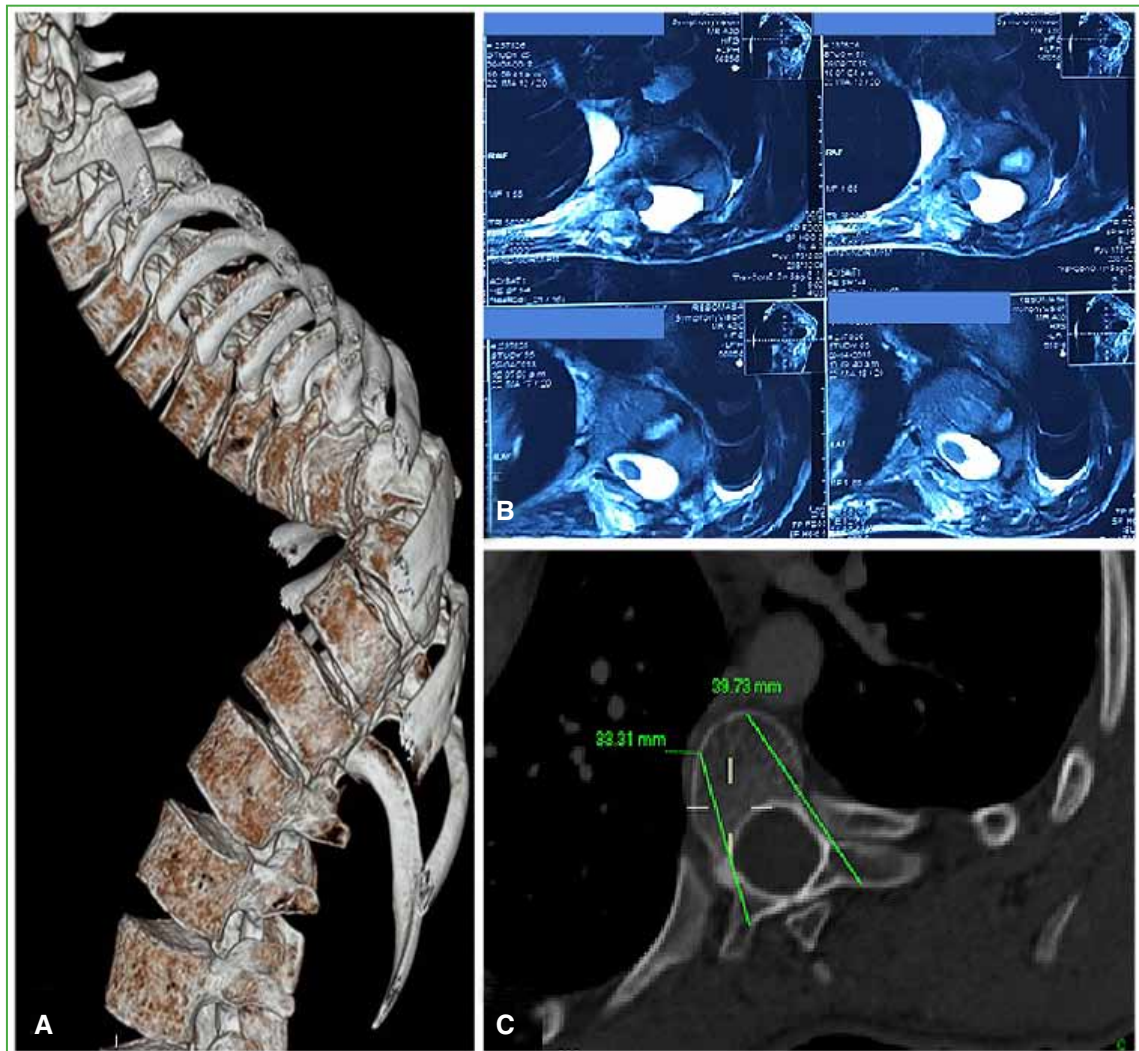


Figure 3. A and C. Multisection helical computed tomography showing vertebral wedging, pedicular dysplasia, angulated vertebra, and rib thinning. B. Magnetic resonance imaging showing dural ectasia.

Due to the stiffness of the kyphosis and scoliosis deformities, a two-stage posterior corpectomy was considered, which involved two shorter surgeries and less surgery-associated blood loss. The surgical risk using the FOCOS score⁸ was 32, i. e., a FOCOS level 5, which entails up to an 80% risk of suffering a major complication during surgery. Pulmonary function testing revealed severe restrictive pulmonary function (secondary to scoliosis) and these spirometry values: forced expiratory volume in 1 second, 40%; forced vital capacity, 36%. Preoperative assessment resulted in cardiac risk II, ASA score II, and moderate pulmonary risk.

In such setting, the surgery was performed. The first surgical stage involved fixation with pedicle screw placement from T4 to L3 using a free-hand technique, with no fixation at the T9-T10 segment, and Ponte osteotomies at T7-T8 and T11-T12 levels. The first surgical stage took 4 hours and the total blood loss was 400cc. The second surgical stage involved the T9-T10 segment posterior release and T9 posterior corpectomy, which had to be postponed due to a sudden decrease in motor evoked potentials that was diagnosed as spinal cord shock. Spinal cord injury management was immediately instituted, following the NASCIS III protocol,⁹ with 30mg/kg methylprednisolone bolus, and 5.4mg/kg for 23 hours. Upon regaining consciousness, the patient presented with no sequelae and an ASIA score of E. The second surgical intervention took 7 hours and 40 minutes, and the total blood loss was 1000cc. The third surgical intervention completed the T9 corpectomy (Figure 4) and T8 and T10 discectomies using autograft-filled titanium mesh replacements; posterior autograft and allograft were placed and, finally, rods. The third surgical intervention took 6 hours and 30 minutes, and the total blood loss was 1500cc.

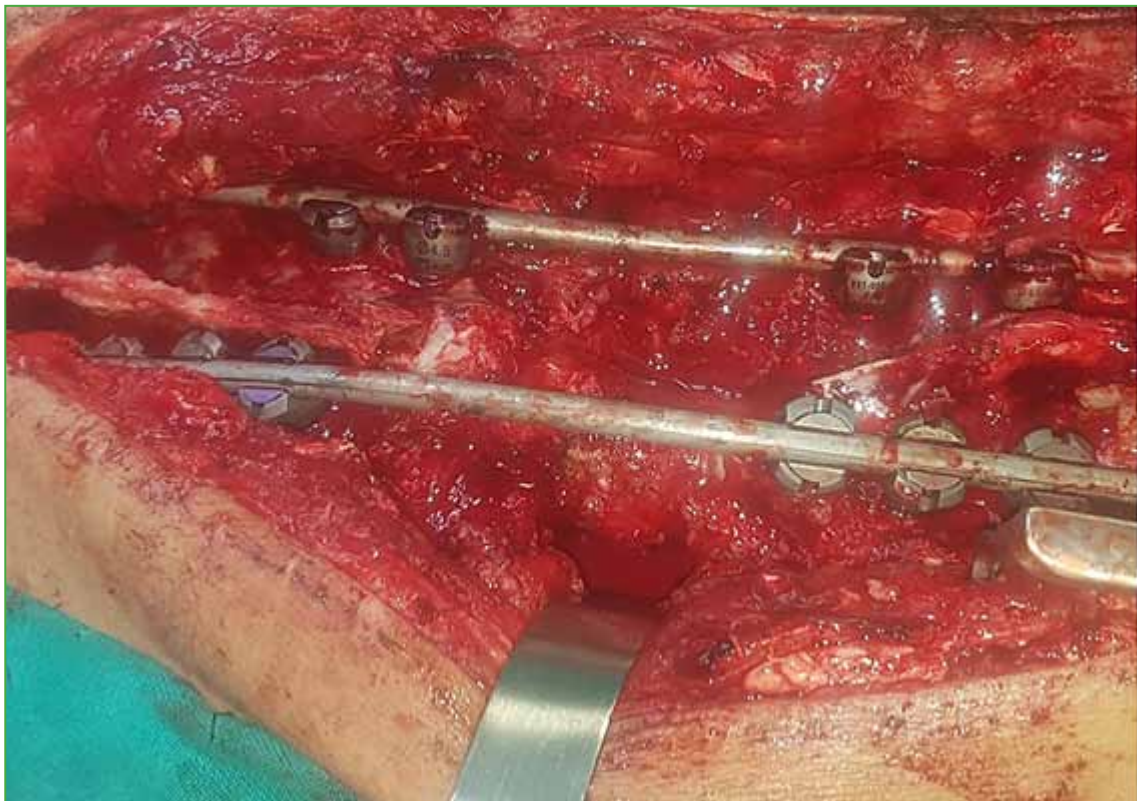


Figure 4. Spinal continuity interruption following the vertebral column resection and kyphoscoliosis correction.

The overall surgical time was of 18 hours and 10 minutes, with a total blood loss of 2900cc. The patient remained hospitalized for 27 days, 3 of them in the intensive care unit. Postoperative immobilization was performed with a plaster corset for 6 months. The 6-month CT evaluation showed graft integration, and the plaster corset was consequently removed. At 1-year follow-up, the patient was 159.5cm tall and weighed 47.8 kg, with a body mass index (BMI) of 18.7. Postoperative radiographic measurements: Cobb angle of the main thoracic curve, 43°; Cobb angle of the proximal thoracic curve, 7°; there was a 59.8% and 86.6% correction, respectively; and coronal balance was -12.9mm, with balanced shoulders. Sagittal plane radiographic evaluation revealed a 48.6° segmental kyphosis, a 59.8° kyphosis at T4-T12, a -0.1 mm sagittal balance, a 69° lumbar lordosis, a 41.2° pelvic incidence, a 7.8° pelvic inclination, and a 33.4° sacral slope (Figure 5).

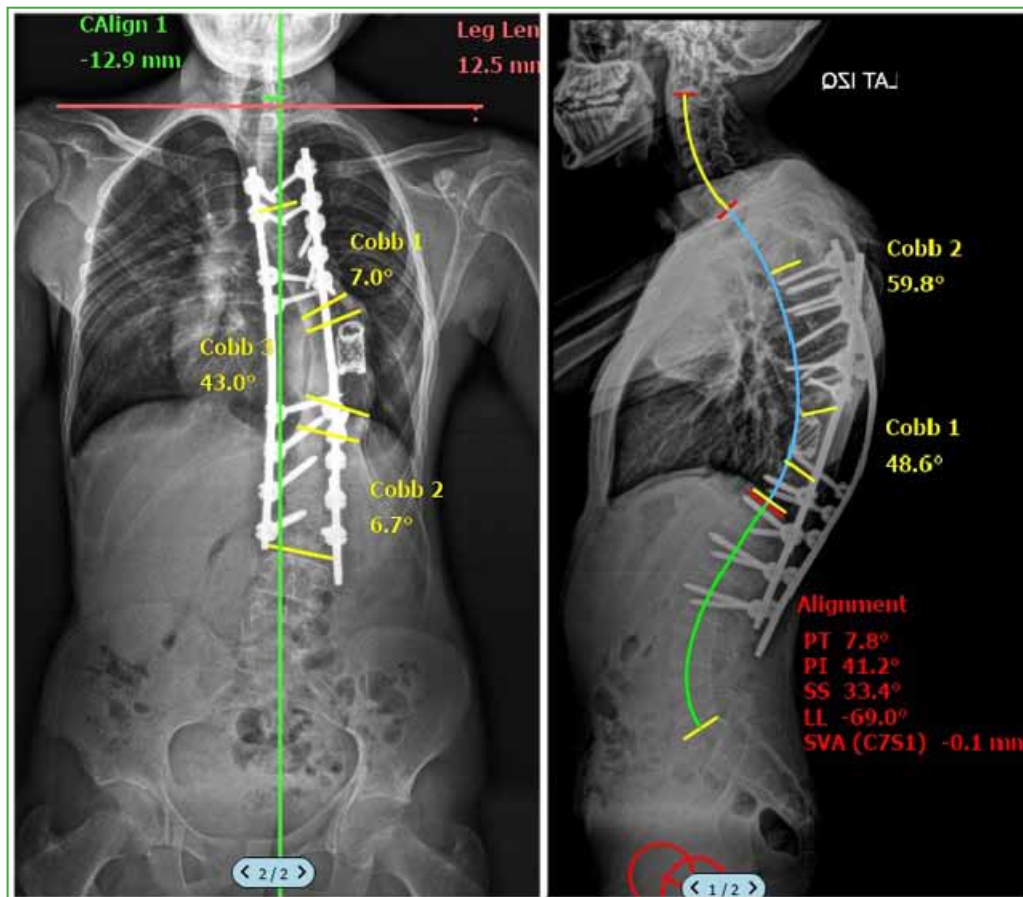


Figure 5. Anteroposterior and lateral spinal radiography: Cobb angle of 43°, -12.9mm coronal balance, 48.6° segmental kyphosis, 59.8° overall kyphosis, and -0.1 mm sagittal balance.

The patient was painless and was able to walk without impediment. Lower-limbs muscle strength was 5/5, and sensory functions were normal (Figure 6). The patient reports having returned to mild-moderate physical activity without suffering shortness of breath. SRS 22 score at 1-year follow-up was of 4.5/5 (function 4.4/5; pain 4.8/5; self-image 4.2/5; mental health 4.4/5; management satisfaction/dissatisfaction 5/5). At 2-year follow-up, the patient was 161cm tall and weighed 48.9kg, with an 18.8 BMI. Radiographic measurements: Cobb angle of the main thoracic curve, 43.1°, and Cobb angle of the proximal thoracic curve, 7°, showing no changes with respect to the previous year's values; and coronal balance was +19.5mm, with balanced shoulders. Sagittal plane radiographic evaluation revealed a steady 48.6° segmental kyphosis as well as a 59.7° kyphosis at T4-T12, a 0.1 mm sagittal balance, a 65.7° lumbar lordosis, a 41.0° pelvic incidence, a 10.4° pelvic inclination, and a 30.6° sacral slope (Figure 7). There was no evidence of titanium mesh subsidence. The patient had returned to full sports activities. SRS 22 score at 2-year follow-up was of 4.7/5 (function 5/5; pain 5/5; self-image 4.4/5; mental health 4.2/5; management satisfaction/dissatisfaction 5/5).

DISCUSSION

Scoliosis is one of the most common musculoskeletal manifestations in neurofibromatosis patients, with an occurrence of 10%–64%.^{1,2,6,10-11} Nondystrophic scoliosis treatment is similar to idiopathic scoliosis. The challenge lies in treating dystrophic scoliosis in NF-1, which typically have an early-onset, acute angulation involving short segments, significant kyphosis, and the characteristics of the involved vertebrae.^{2,12} Our patient met the criteria for dystrophic scoliosis, as showed in Figure 3.

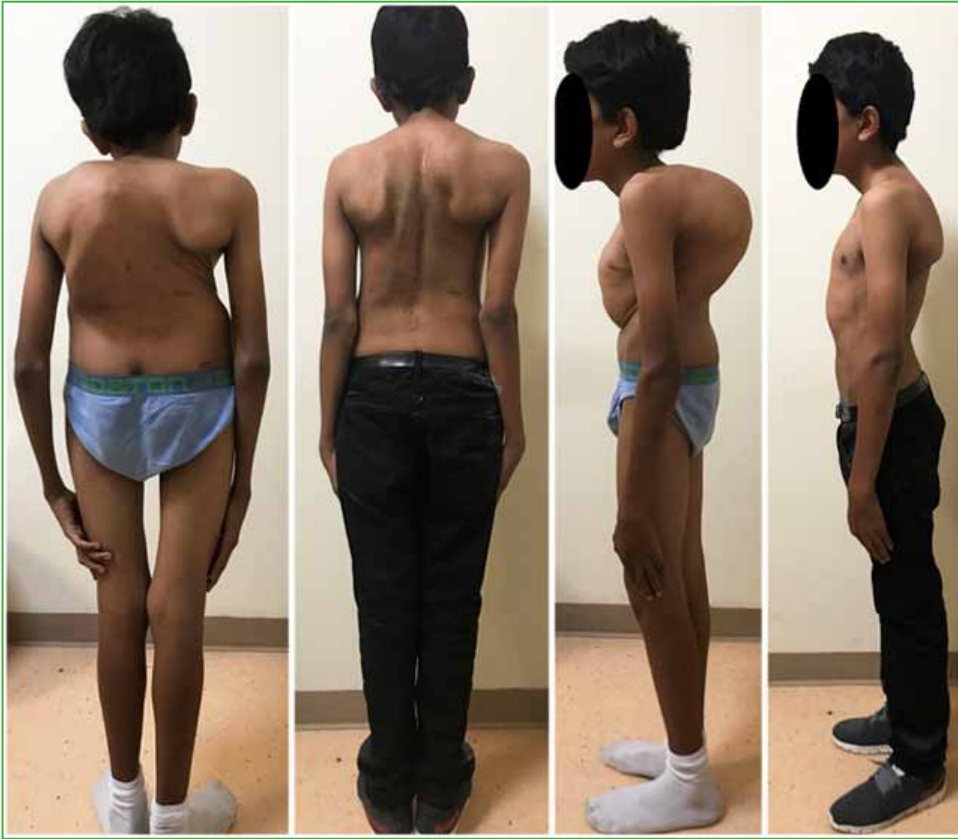

Figure 6. Comparative lateral and frontal view clinical photographs from before and after surgery.

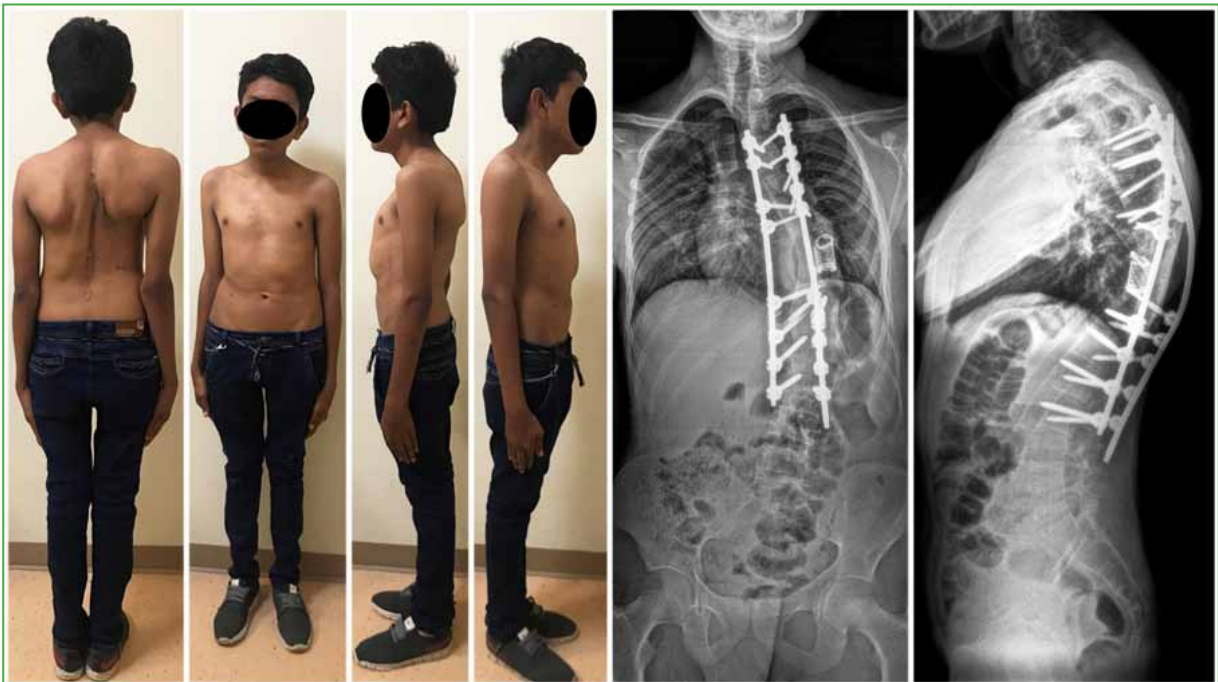


Figure 7. Clinical photographs and radiographs from the two-year follow-up.

Literature states that dystrophic scoliosis, due to its aggressive nature, should only be managed with conservative treatment in curves less than 20°, unlike idiopathic scoliosis, for which surgical treatment may wait until 40-50°. For dystrophic scoliosis, surgical treatment should be performed with curves equal to or greater than 20°. Our patient presented with severe scoliosis, a Cobb coronal angle of 107°, and segmental kyphosis of 110.7°. Owing to the regular timely management of these deformities, such findings are currently scarcely seen at presentation; therefore, their correction is considered a real challenge not only involving the surgical procedure in itself but also for the high rate of complications it involves. The images show a significant coronal and sagittal imbalance, which requires an approach that would address both deformity and plane imbalance correction.

Our surgical strategy included posterior spine fixation from T4 to L3, T9 posterior corpectomy with titanium mesh replacement, and Ponte osteotomies at T7-T8 and T11-T12 levels. The FOCOS score⁸ is a method of surgical risk stratification based on preoperative risk factors and preoperative planning; the risk level predicts the occurrence of general and neurologic complications. Some procedures, such as osteotomies and VCR, are independent predictive factors for postoperative neurologic complications. The FOCOS score ranges from level 1 to 5; the higher the level, the higher the risk of sustaining a major complication, such as a neurologic complication. Our patient was level 5, with an 80% risk of suffering complications. The two-stage surgery was proposed owing to the average surgical time of said level, 367.2 ± 169.1 minutes, and estimated blood loss, 56.6±24.2% of the total blood volume.

Our overall surgical time was of 1090 minutes (3 surgeries), with a blood loss of 2900cc, amounting to 99% of the total calculated blood volume. Although there were no major long-term complications, there was a decrease in motor and somatosensory evoked potentials during the second surgery, which was diagnosed as spinal cord shock and managed following the NASCIS III protocol. Upon regaining consciousness, the patient made a full recovery (ASIA score E), which is consistent with FOCOS level 5 risk patients who have up to 42.1% chance of experiencing neurologic monitoring change.

During the past two decades, the treatment approach for severe kyphoscoliosis spinal deformities of the spine has been practically limited to the posterior-only approach, known as VCR, technique which has been popularized by Lenke *et al.*¹³ and aims at splitting the spine into two segments to allow for later been jointed and, thus, correcting the deformity. Creating such segmental defect results in considerable instability that requires provisional instrumentation to prevent spinal cord damage. VCR is a difficult and challenging procedure that should only be practiced by experienced surgeons. According to Schwab classification,¹⁴ VCR is a grade 5 procedure, involving removal of a vertebral body and both adjacent discs¹⁵ and requires anterior support in defects greater than 5mm. The average surgical time is 6.6-9 hours, with an estimated blood loss of 1600-2280cc.^{13,16}

Complications rate in this type of osteotomies range from 58.5-70.6%.^{13,16} Auerbach *et al.*¹⁷ identified 3 risk factors for major complications: sagittal imbalance of 40mm or more, age 60 years and older, and the presence of 3 or more comorbidities; they also identified a significant association with surgical time greater than 8 hours. Most common intraoperative complications are lost neurogenic motor evoked potentials (27-29%) and blood loss >2000cc. In our case, both these complications occurred, with an overall blood loss of 2900cc (3 surgeries), the greatest intraoperative blood loss being of 1500cc. The deformity level, a blood loss that exceeds the estimated value, and the surgical time are associated with intraoperative complications.¹³ Lenke *et al.*¹³ report that there is no significant difference between perioperative and postoperative complications when comparing single-stage versus 2-stage surgeries, except for a more prolonged surgical time and the blood loss. The most common early complications are respiratory-related, including pneumonia, pleural effusions, and atelectases. Major complications in this type of surgeries range between 17% and 70.6%,^{13,16,18-20} with 8-35% being neurologic complications.

Our patient had no postoperative complications nor neurologic sequelae. Instrumentation failure rate is 14.3%, which commonly takes place within the first 2 years;²¹ failure risk factors include: anterior column defect >20mm, titanium mesh subsidence >5mm, and BMI>27. As of the 2-year follow-up, the patient had presented none of such complications and implant integration has been evidenced through CT scanning.

VCR is recommended in stiff curves, with flexibility < 35%,¹ or when a >40° deformity reduction is attempted, achieving scoliosis and kyphoscoliosis correction of 54-67.2% and 60-90.9%, respectively.^{20,22} In our case, we achieved 62.1° (56.1%) segmental kyphosis correction, 64° (59.8%) scoliosis correction, and 70.5° (54.1%) overall kyphosis correction, with coronal and sagittal imbalance correction (21.8mm and 71.9mm improvement, respectively), with no significant changes at the two-year follow-up.

The SRS 22 questionnaire evaluates the patient's level of satisfaction and performance before and after surgery,⁷ addressing five clinical domains: function, pain, self-image, mental health, and management satisfaction. The SRS 22 is a valid and reliable way to measure the quality of life in scoliosis patients.²³ The SRS 22 has proven that surgery results in pain as well as the other domains improvement up to two years after surgery.²⁴ The global score of our patient has had a favorable progression: 2.8 before surgery, 4.5 at one-year follow-up, and 4.7 at two-year follow-up; with a significant improvement in self-image, mental health, and management satisfaction, which reflects the clinical success in terms of patient perception.

CONCLUSIONS

The VCR is a powerful and demanding surgical technique that allows for the management of the complex kyphoscoliosis deformity to achieve spinal balance; however, it is not without complications, especially neurological and pulmonary complications, which may be unavoidable. The patient's quality of life has improved significantly.

Conflict of interests: Authors claim they do not have any conflict of interests.

E. Morales Vásquez ORCID: <https://orcid.org/0000-0002-0424-872X>

R. Macchiavello Falcon ORCID: <https://orcid.org/0000-0002-3867-783X>

REFERENCES

1. Wang Z, Fu C, Leng J, Qu Z, Xu F, Liu Y. Treatment of dystrophic scoliosis in neurofibromatosis type 1 with one-stage posterior pedicle screw technique. *Spine J* 2015;15(4):587-85. <https://doi.org/10.1016/j.spinee.2014.10.014>
2. Bersusky E. Deformidades vertebrales por neurofibromatosis. *Rev Asoc Argent Ortop Traumatol* 1999;64(4):263-9. https://www.aaot.org.ar/revista/1993_2002/1999/1999_4/640401.pdf
3. Coca Pérez A, Heredero JJ, Burgos J, Ferrero A, Aparicio-Meix JM. Neurofibromatosis tipo 1: escoliosis distrófica y tumor paravertebral. *Rev Esp Pediatr* 2004;60(3):243-5. <https://pesquisa.bvsalud.org/portal/resource/pt/ibc-37743>
4. Woodrow C, Clarke A, Amirfey R. Neurofibromatosis. *Orthop Trauma* 2015;29(3):206-10. <https://doi.org/10.1016/j.mporth.2015.02.004>
5. Patel N B, Stacy GS. Musculoskeletal manifestations of neurofibromatosis type 1. *AJR Am J Roentgenol* 2012;199(1):W99-106. <https://doi.org/10.2214/AJR.11.7811>
6. Crawford AH, Herrera-Soto J. Scoliosis associated with neurofibromatosis. *Orthop Clin North Am* 2007;38(4):553-62. <https://doi.org/10.1016/j.ocl.2007.03.008>
7. Haher TR, Gorup JM, Shin TM, Homel P, Merola AA, Grogan DP, et al. Results of the Scoliosis Research Society instrument for evaluation of surgical outcome in adolescent idiopathic scoliosis. *Spine* 1999;24(14):1435-40. <https://doi.org/10.1097/00007632-199907150-00008>
8. Boachie-Adjei O, Yagi M, Sacramento-Dominguez C, Akoto H, Cunningham ME, Gupta M, et al. Surgical risk stratification based on preoperative risk factors in severe pediatric spinal deformity surgery. *Spine Deform* 2014;2(5):340-9. <https://doi.org/10.1016/j.jspd.2014.05.004>
9. Tejada Barreras M. Esteroides en lesión medular postraumática aguda. *Columna* 2011;1(2):39-42. <https://www.medigraphic.com/pdfs/columna/col-2011/col112d.pdf>
10. Motono N, Kawaguchi M, Kawaharab N, Uramoto H. Case report of surgical treatment of scoliosis caused by neurofibroma located posterior mediastinum. *Int J Surg Case Rep* 2018;53:168-70. <https://doi.org/10.1016/j.ijscr.2018.10.071>
11. Tsirikos AI, Saifuddin A, Noordeen MH. Spinal deformity in neurofibromatosis type-1: diagnosis and treatment. *Eur Spine J* 2005;14(5):427-39. <https://doi.org/10.1007/s00586-004-0829-7>
12. Larson AN, Ledonio CGT, Brearley AM, Sucato DJ, Carreon LY, Crawford AH, et al. Predictive value and interrater reliability of radiographic factors in neurofibromatosis patients with dystrophic scoliosis. *Spine Deform* 2018;6(5):560-7. <https://doi.org/10.1016/j.jspd.2018.02.011>

13. Lenke LG, Newton PO, Sucato DJ, Shufflebarger HL, Emans JB, Sponseller PD, et al. Complications after 147 consecutive vertebral column resections for severe pediatric spinal deformity. *Spine (Phila Pa 1976)* 2013;38(2):119-32. <https://doi.org/10.1097/BRS.0b013e318269fab1>
14. Schwab F, Blondel B, Chay E, Demakakos J, Lenke L, Tropiano P, et al. The comprehensive anatomical spinal osteotomy classification. *Neurosurgery* 2014;74(1):112-20. <https://doi.org/10.1227/01.neu.0000462076.73701.09>
15. Uribe JS, Schwab F, Mundis GM, Xu DS, Januszewski J, Kanter AS, et al. The comprehensive anatomical spinal osteotomy and anterior column realignment classification. *J Neurosurg Spine* 2018;29(5):565-75. <https://doi.org/10.3171/2018.4.SPINE171206>
16. Atici Y, Balioglu MB, Kargin D, Mert M, Albayrak A, Kaygusuz MA. Analysis of complications following posterior vertebral column resection for the treatment of severe angular kyphosis greater than 100°. *Acta Orthop Traumatol Turc* 2017;51(3):201-8. <https://doi.org/10.1016/j.aott.2017.02.015>
17. Auerbach JD, Lenke LG, Bridwell KH, Sehn JK, Milby AH, Bumpass D, et al. Major complications and comparison between 3-column osteotomy techniques in 105 consecutive spinal deformity procedures. *Spine (Phila Pa 1976)* 2012;37(14):1198-210. <https://doi.org/10.1097/BRS.0b013e31824ffffde>
18. Wang S, Aikenmu K, Zhang J, Qiu G, Guo J, Zhang Y, Weng, X. The aim of this retrospective study is to evaluate the efficacy and safety of posterior-only vertebral column resection (PVCR) for the treatment of angular and isolated congenital kyphosis. *Eur Spine J* 2017;26(7):1817-25. <https://doi.org/10.1007/s00586-015-4344-9>
19. Sacramento-Domínguez C, Yagi M, Ayanga J, Nemani VM, Akoto H, Mahmud R, et al. Apex of deformity for three column osteotomy. Does it matter in the occurrence of complications? FOCOS Spine Research Group. *Spine J* 2015;15(11):2351-9. <https://doi.org/10.1016/j.spinee.2015.07.010>
20. Sheha ED, Kim HJ, Cunningham ME. Vertebral column resection for complex spinal deformity. *Semin Spine Surg* 2017;29(4):175-83. <https://doi.org/10.1053/j.semss.2017.08.002>
21. Wang H, Guo J, Wang S, Yang Y, Zhang Y, Qiu G, Zhang J. Instrumentation failure after posterior vertebral column resection in adult spinal deformity. *Spine (Phila Pa 1976)* 2017;42(7):471-8. <https://doi.org/10.1097/BRS.0000000000001844>
22. Sravisht Iyer, Venu M, Nemani, Han Jo Kim. A review of complications and outcomes following vertebral column resection in adults. *Asian Spine J* 2016;10(3):601-9. <https://doi.org/10.4184/asj.2016.10.3.601>
23. Climent JM, Bagó J, Rodríguez-Ruiz C, Sánchez-Raya J, Mulet S, Cholbi F. Nueva estrategia para mejorar la medida de la calidad de vida en la escoliosis idiopática: adición de la dimensión de deformidad percibida al cuestionario de la Scoliosis Research Society (SRS-22). *Rehabilitación* 2011;45(3):228-32. <https://doi.org/10.1016/j.rh.2011.04.007>
24. Merola AA, Maher TR, Brkaric M, Panagopoulos G, Mathur S, Kohani O, et al. A multicenter study of the outcomes of the surgical treatment of adolescent idiopathic scoliosis using the Scoliosis Research Society (SRS) outcome instrument. *Spine (Phila Pa 1976)* 2002;27(18):2046-51. <https://doi.org/10.1097/00007632-200209150-00015>