

Slalom Technique as a Treatment in Multilevel Lumbar Spinal Stenosis. Series of Cases Treated Simultaneously with Endoscopic and Tubular Decompression with Microscopic Assistance.

Nicolás Coombes, Eduardo Galaretto, Juan Pablo Guyot, Norberto Fernández, Cristian Fuster

Axial Grupo Médico (Buenos Aires, Argentina)

ABSTRACT

Introduction: Unilateral laminectomy for bilateral decompression (ULBD) by single approach has become relevant in patients with multilevel stenosis- When it is performed at more than one level with a single approach, alternately and crosswise to the previous approach, it is known as “slalom” technique. The objective of this article is to present a series of cases treated with the slalom technique with simultaneous bilateral endoscopic and microscopic assistance, in patients with multilevel lumbar canal stenosis.

Materials and Methods: Retrospective analysis of patients treated simultaneously from January 2017 to January 2018, all operated by the same surgical team with tubular separators and simultaneous endoscopic and microscopic assistance. **Results:** Four patients, all male, with an average age of 73.5 years with multilevel lumbar pathology, were included. In total, 10 segments were decompressed (2.5 levels per patient, on average), with an average surgical time of 107 minutes. There were no associated complications, the patients were discharged within the day of surgery. **Conclusions:** The minimally invasive Slalom technique is a very effective procedure to resolve symptoms of multilevel stenosis associated with a bilateral combined technique with two surgical teams, resulting in a viable option for the treatment of this type of patient.

Key words: Lumbar spinal stenosis; over the top decompression; surgical slalom; minimally invasive lumbar decompression.

Level of Evidence: IV

Técnica de “slalom” quirúrgico en estenosis de canal lumbar multinivel. Serie de casos tratados de manera simultánea con descompresión endoscópica y tubular con asistencia microscópica bilateral

RESUMEN

Introducción: La laminectomía unilateral para descompresión bilateral por abordaje único ha tomado relevancia en pacientes con estenosis multinivel, cuando se realiza en más de un nivel por un abordaje único, de manera alterna y de forma cruzada, al abordaje anterior es conocida como técnica de “slalom”. El **objetivo** de este artículo es presentar una serie de casos tratados con la técnica de “slalom” con asistencia endoscópica y microscópica bilateral, simultánea, en pacientes con estenosis de canal lumbar multinivel. **Materiales y Métodos:** Análisis retrospectivo de pacientes tratados de forma simultánea, entre enero de 2017 y enero de 2018, todos operados por el mismo equipo quirúrgico con separadores tubulares, y asistencia endoscópica y microscópica simultánea. **Resultados:** Se incluyó a 4 hombres, con una edad promedio de 73.5 años y patología lumbar multinivel. Se descomprimieron 10 segmentos (2,5 media de niveles por pacientes), con un tiempo quirúrgico promedio de 107 minutos. No hubo complicaciones asociadas y los pacientes recibieron el alta hospitalaria el día de la cirugía. **Conclusiones:** La técnica de “slalom” mínimamente invasiva resulta ser un procedimiento muy eficaz para resolver síntomas de estenosis multinivel asociada a una técnica combinada bilateral con dos equipos quirúrgicos para el tratamiento de este tipo de pacientes.

Palabras clave: Canal lumbar estrecho; descompresión cruzada; “slalom” quirúrgico; descompresión lumbar mínimamente invasiva.

Nivel de Evidencia: IV

Received on August 17th, 2019. Accepted after evaluation on September 6th, 2020 • NICOLÁS COOMBES, MD • nicolascoombes@gmail.com  <http://orcid.org/0000-0002-9241-6083>

How to cite this article: Coombes N, Galaretto E, Guyot JP, Fernández N, Fuster C. Slalom Technique as a Treatment in Multilevel Lumbar Spinal Stenosis. Series of Cases Treated Simultaneously with Endoscopic and Tubular Decompression with Microscopic Assistance. *Rev Asoc Argent Ortop Traumatol* 2021;86(2):175-184. <https://doi.org/10.15417/issn.1852-7434.2021.86.2.1013>

INTRODUCTION

As the average age of the population increases, the number of patients suffering from a painful degenerative disease of the lumbar spine increases.^{1,2} Laminectomy has traditionally been considered the treatment of choice for patients with spinal stenosis that does not respond to conservative treatment.³ Isolated open decompression can cause instability and recurrent lumbar pain, leading to fusion surgery.^{4,5}

In recent years, less invasive alternatives to laminectomy have been developed.⁶

Unilateral laminotomy for bilateral decompression, in particular, is considered an effective and safe technique that reduces tissue damage when compared to open techniques.⁷⁻¹⁰

The lumbar decompression surgery called “cross decompression” is performed through a unilateral approach and allows decompression to be achieved bilaterally. When this technique is performed in more than one segment with alternate approaches, it is called the “slalom” technique. This technique has become a surgical treatment option for multilevel degenerative lumbar spinal stenosis.¹¹

In open surgeries, laminectomy is associated with longer skin incisions to reach two or more segments. The muscles must be retracted further and partial resection of the inferior and superior facets must be performed in two or more segments on the same side of the approach. This results in increased unilateral collateral damage to the muscles and joints, which counteracts the microsurgical philosophy of this technique.^{12,13}

The objective of this article is to provide a technical description of the “slalom” alternated multi-level lumbar decompression technique, performed simultaneously with two surgeons, and to communicate the preliminary results.

MATERIALS AND METHODS

We conducted a retrospective analysis of patients who underwent minimally invasive decompression with a multilevel slalom technique for lumbar spinal stenosis between January 2017 and January 2018.

Surgical time, treated segments, operative complications and length of hospital stay were evaluated. All patients were evaluated before surgery, 30 days after surgery and a year after surgery using the visual analog scale. Patient satisfaction was determined using the Weiner scale and modified Macnab criteria.

The four patients in the series presented multilevel lumbar spinal stenosis visible on magnetic resonance imaging (Figure 1), and long-standing radicular pain and gait claudication without segmental instability, which were evaluated on flexion and extension radiographs.

In this series, the diagnoses were: multilevel degenerative disc disease (3 patients), congenital lumbar spinal stenosis (one case), and narrow lumbar canal due to ligamentum flavum hypertrophy (4 patients).

The patients were treated by the same surgical team, simultaneously. Student’s t test was used for the pre-operative and postoperative independent paired variables to obtain their statistical value. The EPI info 7.2.2.6 (2018) program was used. After a partial response to conservative treatments, all patients were scheduled for surgery.

Surgical technique

The surgery was performed simultaneously, with one surgeon per side. One of them performed tubular surgery with endoscopic assistance (EasyGo 1 equipment, Karl-Storz), while, on the contralateral side, an OPMI Pentero 800 microscope (Zeiss) with a METRX tubular separator (Medtronic) was used.

The patient was placed in the prone decubitus position and general anesthesia was administered. Lateral fluoroscopy was used to mark the location of the skin incision. Both surgeons determine the incisions according to the level to be treated (Figure 2).

Both procedures share the same entry system, so dilators and a 20 mm working channel are used (Figure 3).

In order to be able to work simultaneously, decompressions are performed at alternate levels and with the microscope slightly angled so as not to obstruct the movements of the opposing surgeon. This arrangement, together with the use of endoscopic assistance, provides the technical advantage of allowing the use of multiple equipment at the same time and not hindering the maneuvers of the opposing surgeon, because the optic is 25 °. Decompression is performed according to the unilateral laminotomy technique for bilateral decompression described by Hartl *et al.*¹ The objective is to perform a complete flavectomy from the caudal pedicle to the cranial insertion of the ligamentum flavum.

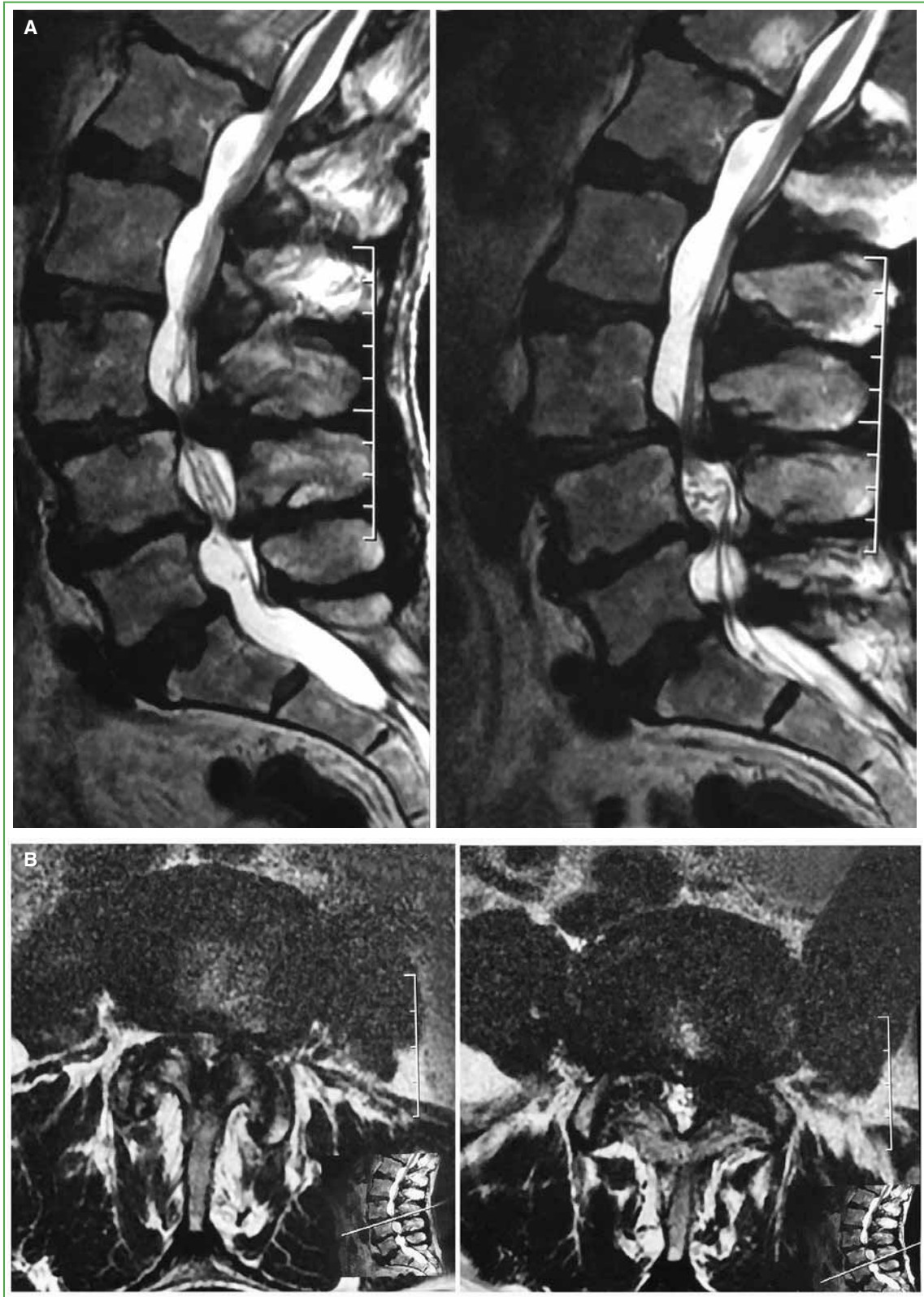

Figure 1. MRI, T2- weighted sequence. **A.** Axial planes. Multilevel spinal stenosis is observed. **B.** Sagittal plane. Multilevel disc compromise is observed.

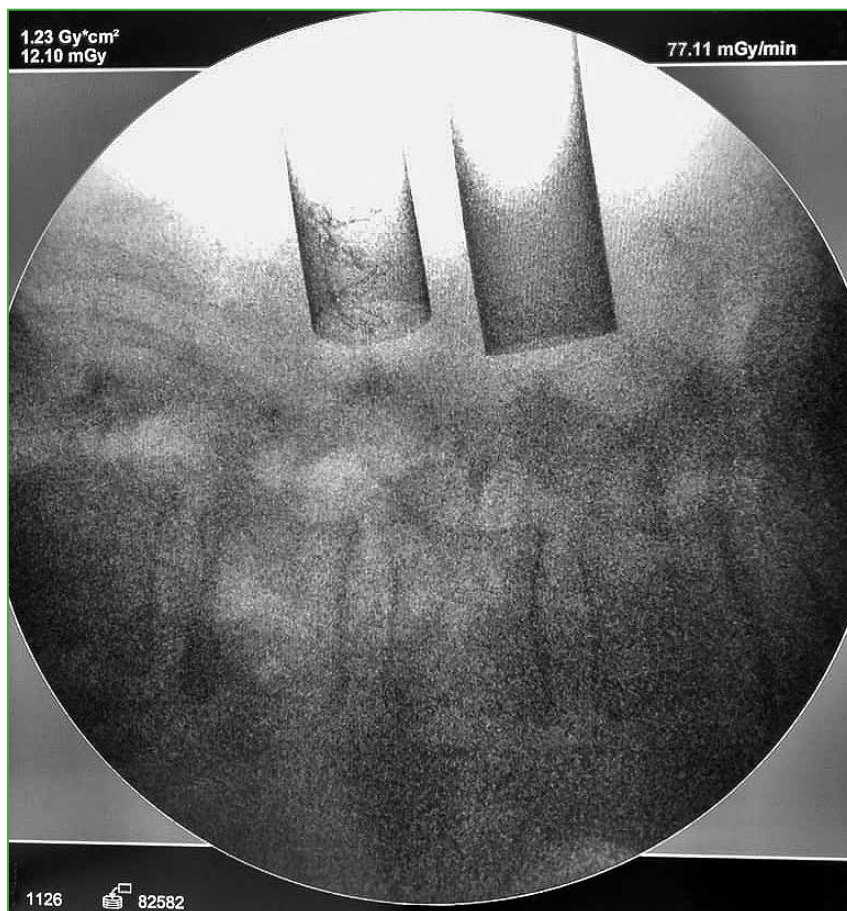


Figure 2. Position of both tubes, lateral view of the image intensifier.



Figure 3. Surgical layout of both systems.

The sequence is different for both sides. The *first stage* could be considered taking as reference the surgeon on the side that uses the microscope and performs decompression ipsilateral to the approach. On the contralateral side, where the endoscope is used, which is located at the supra-adjacent or infra-adjacent level, the surgery begins by cross-decompression next to the approach using the *over the top* technique (Figure 4).

In a *second stage*, taking as a reference the sequence of the surgeon using the microscope, the operating table is tilted together with an angle of the tube towards the midline to perform cross decompression and, on the endoscope side, the side ipsilateral to the approach is decompressed (Figure 5).

Before removing the tube, the site is thoroughly washed with abundant physiological solution. Hemostasis for epidural venous plexus Hermetic closure of the fascia, the subcutaneous cell tissue and the skin.

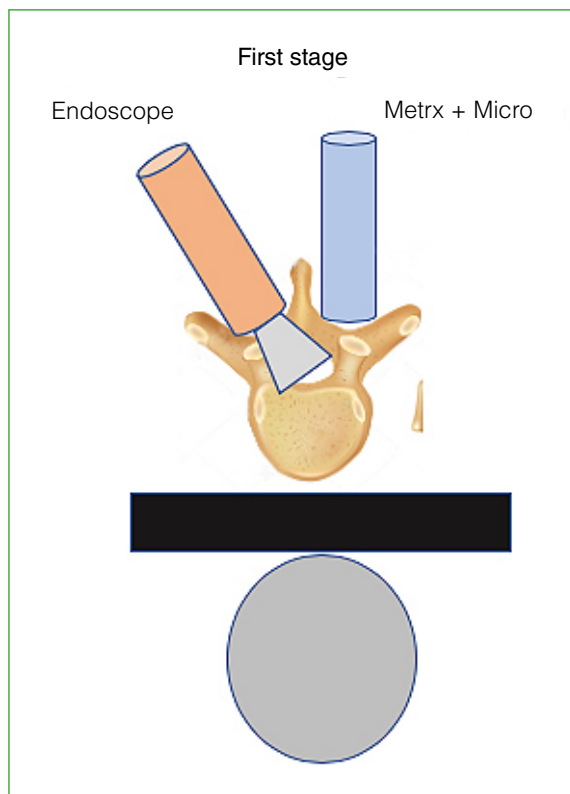


Figure 4. First stage of surgery, taking as a reference the surgeon who uses a microscope. It begins by decompressing the ipsilateral side of the approach. The endoscope is used to decompress the contralateral side.

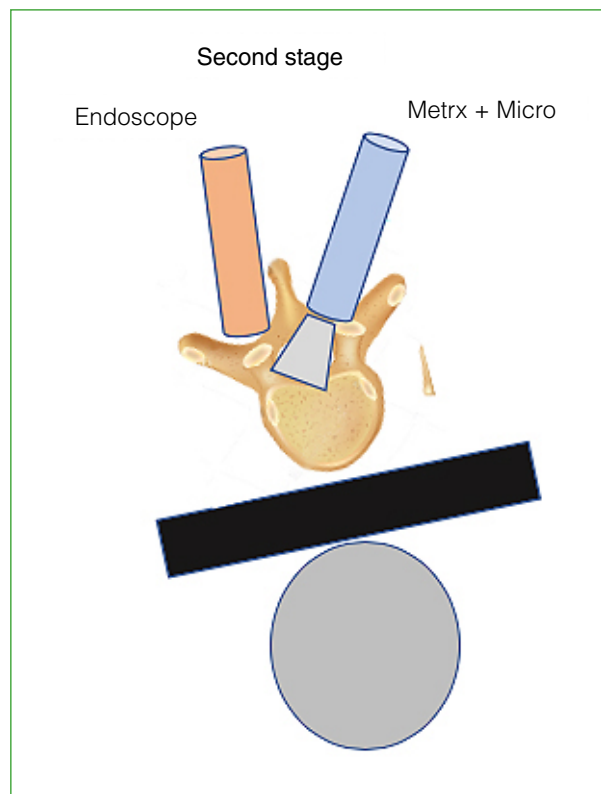


Figure 5. Second stage of surgery. The surgical table is tilted to achieve contralateral decompression with the microscope. The endoscope is used to decompress the side of the approach.

FINDINGS

Between January 2017 and January 2018, four men (mean age 73.5 years, range 70-77) underwent surgery. The comorbidities were 13: systemic arterial hypertension (4 cases), oral anticoagulation (3 cases), chronic obstructive pulmonary disease (2 cases), coronary artery disease / stent placement (3 cases), Parkinson's disease (1 case). The decision on which side to perform each of the techniques was made according to the comfort of the team (Table 1). The total number of decompressed levels was 10 (average 2.5 levels per patient) with involvement between L2 and L5. The most compromised segments were L3 and L4 in 70% of the cases, followed by L5 and L2. The average surgical time was 107.75 min (range 86-123) and no complications were recorded during the procedure.

Table 1. Demographic data

Demographic data	
Number of patients	4
Sex	M
Age	73,5 (70-77)
Previous blocks	51
Comorbidities	13
Systemic hypertension	4
Oral anticoagulation	3
COPD	2
Heart disease	3
Parkinson's disease	1

In the immediate postoperative period, patients were instructed to walk 2 hours after the end of the surgery. All patients were discharged after an average hospital stay of 11.5 h (range 9-18). There were no complications in the immediate postoperative period nor in the follow-up, which, on average, lasted 26 months (range 18-33) (Table 2).

Using the modified Macnab satisfaction criteria, three patients rated the outcome as excellent and one as very good. According to the Weiner scale, the four patients perceived that the procedure had been very or quite successful and would recommend it to other patients.

The improvement in the clinical results obtained was very favorable, the average VAS score was 8/10; in the immediate postoperative period it was 2/10 ($p < 0.05$) and after one year it was 2.2 / 10.

Table 2. Surgical data and levels treated

Surgical data	
Time	107,7 (86-123)
Stay	11,5 hr. (9-18 hr.)
Complications	No
Revisions	No
Affected levels	10
L2-L3	1
L3-L4	4
L4-L5	4
L5-S1	1

Figure 6 and Table 3 summarize the postoperative clinical assessment using the visual analog scale and satisfaction according to the modified MacNab and Weiner criteria.

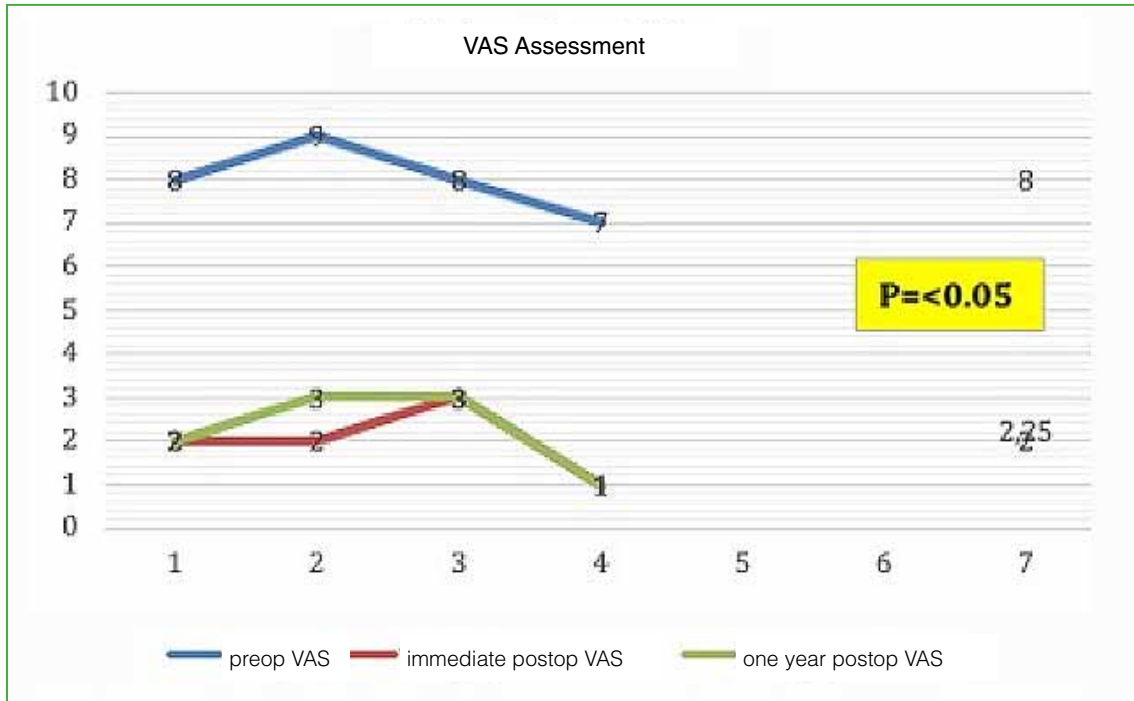


Figure 6. Visual analog scale in the immediate postoperative period and one year after surgery with a significant improvement ($p < 0.05$).

Table 3. Postoperative satisfaction results according to the modified Macnab and Weiner criteria.

Postoperative satisfacion	
Modified macnab	
Excellent	3/4
Good	1/3
Fair	
Poor	
Weiner	
Successful	2/4
Quite successful	2/4
Not very successful	
Failure	

DISCUSSION

The progressive advance in life expectancy and quality of life, together with the possibility of having better diagnostic options, have made spinal stenosis the most frequent pathology in spinal centers in the Western world.^{4,8} Conventional laminectomy has been the traditional surgical treatment for decades. Although the postoperative development of segmental instability is a multifactorial problem, unnecessary damage to the anatomical structures that stabilize the capsuloligamentary complex has always been a problem with this technique.¹⁴ At the same time, with this surgical strategy, the possibility of scar tissue formation and epidural fibrosis increases with the potential appearance of radicular symptoms in the postoperative period.^{12,13}

Cross-over decompression using a unilateral approach has certain advantages: it significantly minimizes the risks of epidural fibrosis, the muscles retract only on one side, and the area of the spinal canal that is exposed to the surrounding tissue remains small. This reduces the area of potential scar formation. Furthermore, the integrity of the contralateral facet joint remains almost completely intact.¹¹ These advantages are generally lost in patients with multisegmental diseases that represent more than 50% of the population in people > 65 years.¹⁵

At the same time, in patients with multisegmental pathologies, performing a unilateral approach entering always through the same side leads to an increase in muscle injury. Furthermore, the elimination of the medial part of the descending facet in two or more levels of the same side can cause unilateral functional problems. This becomes even more important when spinal stenosis is associated with a degenerative deformity, such as degenerative spondylolisthesis or *de novo* scoliosis.^{16,17}

The “slalom” technique could be an option to minimize collateral damage or make it more balanced while maintaining the advantages of minimally invasive surgery in selected patients. Although this was a small series of patients, there were no complications.

In most reports, the described technique is used to treat each segment in a deferred way. The results of the tandem treatment of multiple segments with bilateral microscopic assistance have recently been published and the functional results were similar to those of our series.¹⁸

We have not found reports on the treatment with simultaneous combined techniques for this condition. In our case, the use of two different methods (endoscope and microscope) is due to different learning curves, but mainly to a better use of the physical space of the operating room.

Limitations and advantages

This series shows the first results of our experience with a new technique. Surgical time is likely to decrease with an increasing learning curve.¹⁹ The objective was to present a technical note on how we plan the treatment in this type of pathology. We consider it an advantage to be able to use this technique in patients with multiple comorbidities to avoid admission to the operating room in stages.

An obvious limitation and challenge of this technique is the increased need for resources, as it requires access to an endoscope, and its learning curve. In our case, we used it due to the lack of access to another microscope and the reduced space within the operating room.

CONCLUSIONS

The results summarize our first experience with simultaneous combined techniques for multilevel minimally invasive lumbar decompression. This technique is safe and allows to obtain very good results. It could be considered as a valid option to treat patients with multilevel lumbar spinal stenosis and multiple comorbidities, as it is an effective technique to alleviate symptoms and, when performed in combination with two teams, would avoid the need for multiple interventions.

Conflict of interests: The authors declare they do not have any conflict of interests.

E. Galaretto ORCID ID: <https://orcid.org/0000-0003-4121-8228>
 J. P. Guyot ORCID ID: <https://orcid.org/0000-0001-6524-4426>

N. Fernández ORCID ID: <https://orcid.org/0000-0002-5250-5399>
 C. Fuster ORCID ID: <https://orcid.org/0000-0002-5293-0846>

REFERENCES

- Costa F, Sassi M, Cardia A, Ortolina A, De Santis A, Luccarell G, et al. Degenerative lumbar spinal stenosis: analysis of results in a series of 374 patients treated with unilateral laminotomy for bilateral microdecompression. *J Neurosurg Spine* 2007;7(6):579-86. <https://doi.org/10.3171/SPI-07/12/579>
- Deyo RA, Ciol MA, Cherkin DC, Loeser JD, Bigos SJ. Lumbar spinal fusion. A cohort study of complications, reoperations, and resource use in the Medicare population. *Spine (Phila Pa 1976)* 1993;18(11):1463-70. PMID: 8235817
- Becker P, Bretschneider W, Tuschel A, Ogon M. Life quality after instrumented lumbar fusion in the elderly. *Spine (Phila 1976)* 2010;35(15):1478-81. <https://doi.org/10.1097/BRS.0b013e3181c62294>
- Fredman B, Arinzon Z, Zohar E, Shabat S, Jedeikin R, Fidelman ZG, et al. Observations on the safety and efficacy of surgical decompression for lumbar spinal stenosis in geriatric patients. *Eur Spine J* 2002;11(6):571-4. <https://doi.org/10.1007/s00586-002-0409-7>
- Kilinçer C, Steinmetz MP, Sohn MJ, Benzel EC, Bingaman W. Effects of age on the perioperative characteristics and short-term outcome of posterior lumbar fusion surgery. *J Neurosurg Spine* 2005;3(1):34-9. <https://doi.org/10.3171/spi.2005.3.1.0034>
- Machado GC, Ferreira PH, Yoo RI, Harris IA, Pinheiro MB, Koes BW, et al. Surgical options for lumbar spinal stenosis. *Cochrane Database Syst* 2016;11(11):CD012421. <https://doi.org/10.1002/14651858.CD012421>
- Overdeest GM, Jacobs W, Vleggeert-Lankamp C, Thome C, Gunzburg R, Peul W. Effectiveness of posterior decompression techniques compared with conventional laminectomy for lumbar stenosis. *Cochrane Database Syst Rev* 2015;(3):CD010036. <https://doi.org/10.1002/14651858.CD010036.pub2>
- Oertel MF, Ryang YM, Korinth MC, Gilsbach JM, Rohde V. Long-term results of microsurgical treatment of lumbar spinal stenosis by unilateral laminotomy for bilateral decompression. *Neurosurgery* 2006;59(6):1264-70. <https://doi.org/10.1227/01.NEU.0000245616.32226.58>
- Schöller K, Alimi M, Cong GT, Christos P, Härtl R. Lumbar spinal stenosis associated with degenerative lumbar spondylolisthesis: a systematic review and meta-analysis of secondary fusion rates following open vs. minimally invasive decompression. *Neurosurgery* 2017;80:355-67. <https://doi.org/10.1093/neuros/nyw091>
- Papavero L, Thiel M, Fritzsche E, Kunze C, Westphal M, Kothe R. Lumbar spinal stenosis: prognostic factors for bilateral microsurgical decompression using a unilateral approach. *Neurosurgery* 2009;65(6 suppl):182-7. <https://doi.org/10.1227/01.NEU.0000341906.65696.08>
- Mayer HM. Microsurgical decompression of acquired (degenerative) central and lateral spinal canal stenosis. En: Mayer HM (ed.). *Minimally invasive spine surgery*. Berlin, Germany: Springer; 2000:105-16.
- LaRocca H, Macnab I. The laminectomy membrane: studies in its evolution, characteristics, effects and prophylaxis in dogs. *J Bone Joint Surg Br* 1974;56(3):545-50. <https://doi.org/10.1302/0301-620X.56B3.545>
- Raffo CS, Lauerma WC. Predicting morbidity and mortality of lumbar spine arthrodesis in patients in their ninth decade. *Spine (Phila Pa 1976)* 2006;31(1):99- 103. <https://doi.org/10.1097/01.brs.0000192678.25586.e5>
- Boukebir MA, Berlin CD, Navarro-Ramirez R, Heiland T, Schöller K, Rawanduy C, et al. Ten-step minimally invasive spine lumbar decompression and dural repair through tubular retractors. *Oper Neurosurg (Hagerstown)* 2017;13(2):232-45. <https://doi.org/10.1227/NEU.0000000000001407>
- Hall S, Bartleson JD, Onofrio BM, Baker HL Jr., Okazaki H, O'Duff JD. Lumbar spinal stenosis: clinical features, diagnostic procedures, and results of surgical treatment in 68 patients. *Ann Int Med* 1985;103(2):271-5. <https://doi.org/10.7326/0003-4819-103-2-271>
- Usman M, Ali M, Khanzada K, Ishaq M, Naeem-ul-Haq, Aman R, et al. Unilateral approach for bilateral decompression of lumbar spinal stenosis: a minimal invasive surgery. *J Coll Physicians Surg Pak* 2013;23(12):852-6. PMID: 24304987

17. Arai Y, Hirai T, Yoshii T, et al. A prospective comparative study of 2 minimally invasive decompression procedures for lumbar spinal canal stenosis: unilateral laminotomy for bilateral decompression (ULBD) versus muscle-preserving interlaminar decompression (MILD). *Spine* 2014;39(4):332-40.
<https://doi.org/10.1097/BRS.000000000000136>
18. Wipplinger C, Kim E, Lener S, Navarro-Ramirez R, Kirnaz S, Hernandez RN, et al. Tandem microscopic slalom technique: the use of 2 microscopes simultaneously performing unilateral laminotomy for bilateral decompression in multilevel lumbar spinal stenosis. *Global Spine J* 2020;10(2_suppl):88S-93S.
<https://doi.org/10.1177/2192568219871918>
19. Parikh K, Tomasino A, Knopman J, Boockvar J, Härtl R. Operative results and learning curve: microscope-assisted tubular microsurgery for 1- and 2-level discectomies and laminectomies. *Neurosurg Focus* 2008;25(2):E14.
<https://doi.org/10.3171/FOC/2008/25/8/E14>